



Sick Call Screener Course

Integumentary System

(2.10)



Enabling Objectives

- 1.52 Utilize the knowledge of integumentary system anatomy while assessing a patient with a integumentary complaint
- 1.53 Utilize the knowledge of integumentary system physiology while assessing a patient with a integumentary complaint
- 1.54 Identify types of lesions
- 1.55 Perform a dermatological examination



Enabling Objectives (Cont.)

- 1.56 State signs and symptoms of common dermatological disorders
- 1.57 State treatments for common dermatological disorder
- 1.16 State Red Flag criteria



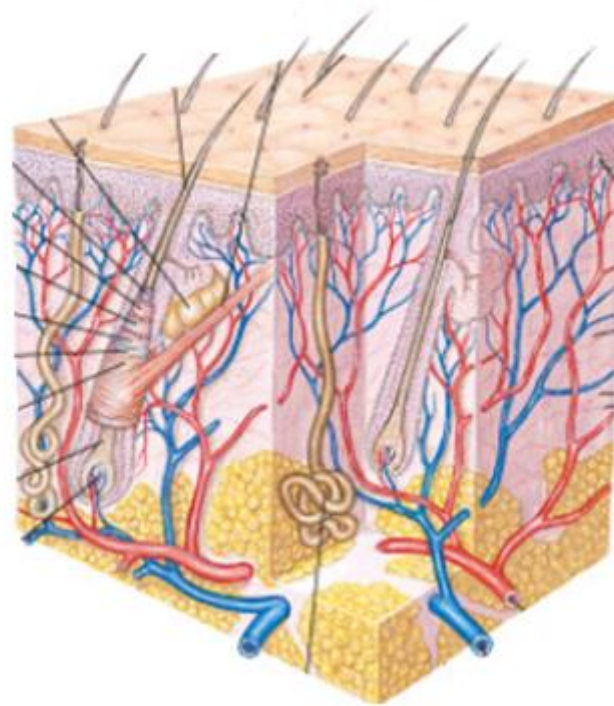
Introduction

- Helps maintain a constant body temperature
- Protects the body
- Provides sensory information about the surrounding environment.



Integumentary System

- Skin
- Hair
- Oil & Sweat Glands
- Nails
- Sensory Receptors



Skin, Hair, and Nails Seidel's Guide to Physical Examination

R³

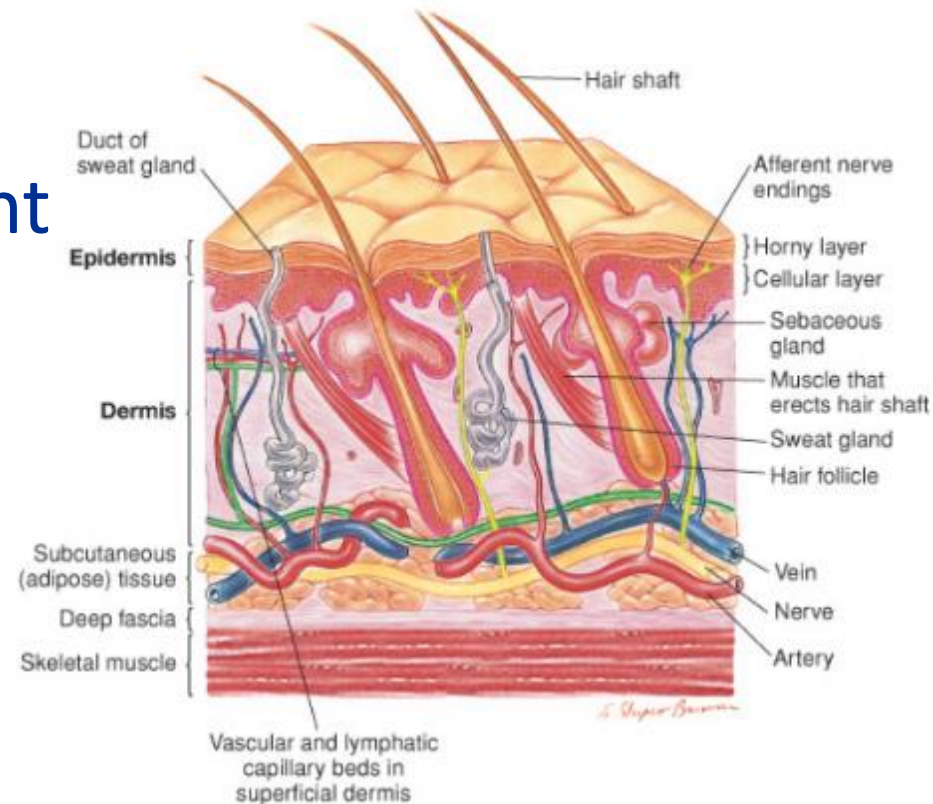
Relevant, Responsive, Requested

2.10.2-5



Epidermis

- Stratum Corneum:
 - Protection from harmful environment
- Cellular Stratum:
 - Keratin cells are synthesized

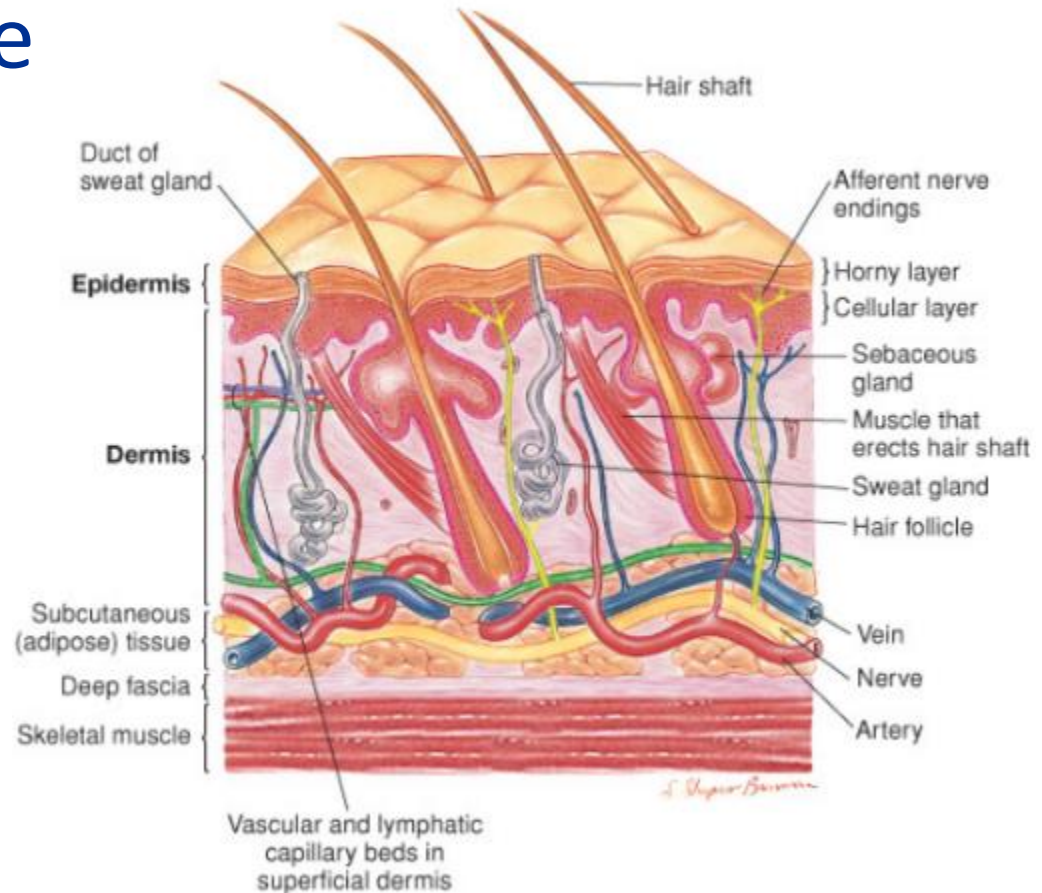


Bates guide to physical examination and history taking [12th ed.]. My Athens/ STAT!Ref



Dermis

- Connective tissue layer of the skin
- Supports and separates the epidermis from the cutaneous adipose tissue

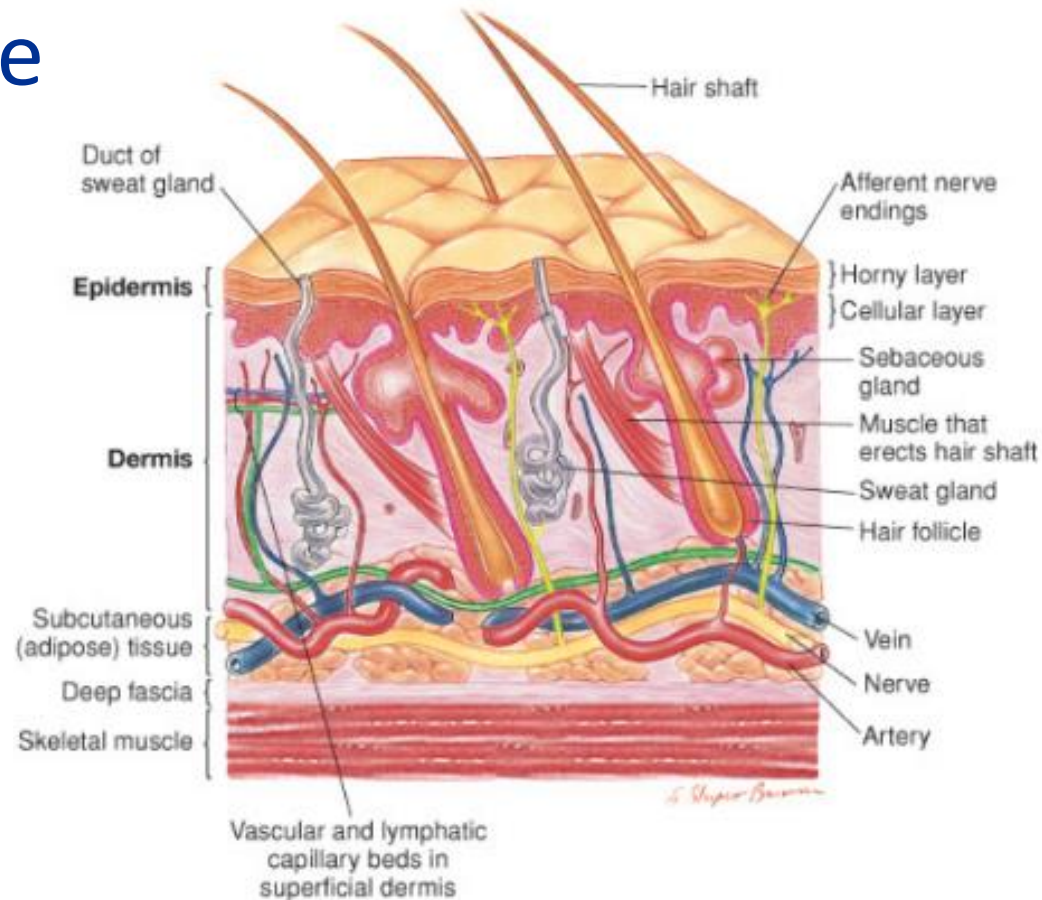


Bates guide to physical examination and history taking [12th ed.]. Philadelphia, PA.) My Athens/ STAT!Ref



Hypodermis

- Also known as the subcutaneous layer (subQ)

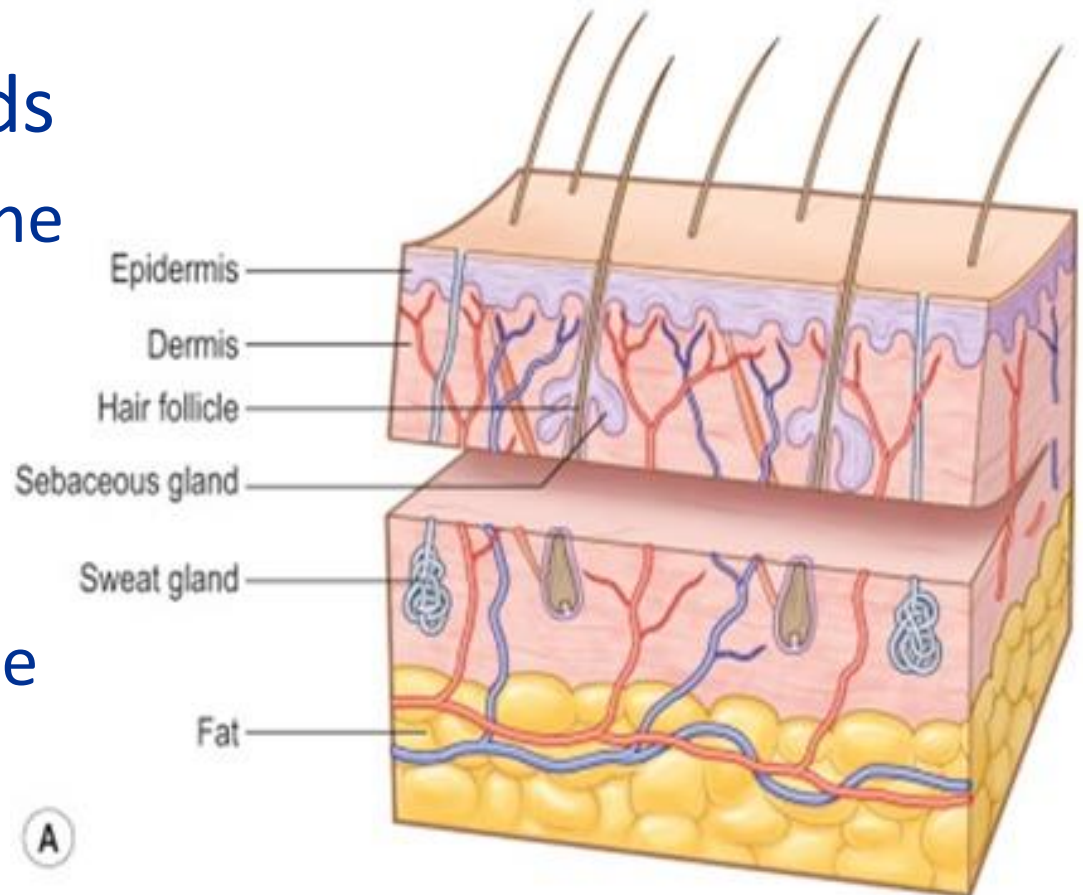


Bates guide to physical examination and history taking [12th ed.]. My Athens/ STAT!Ref



Skin Appendages

- Sebaceous Glands
 - Also known as the Oil Glands
- Sweat Glands
 - The cells of these glands release sweat

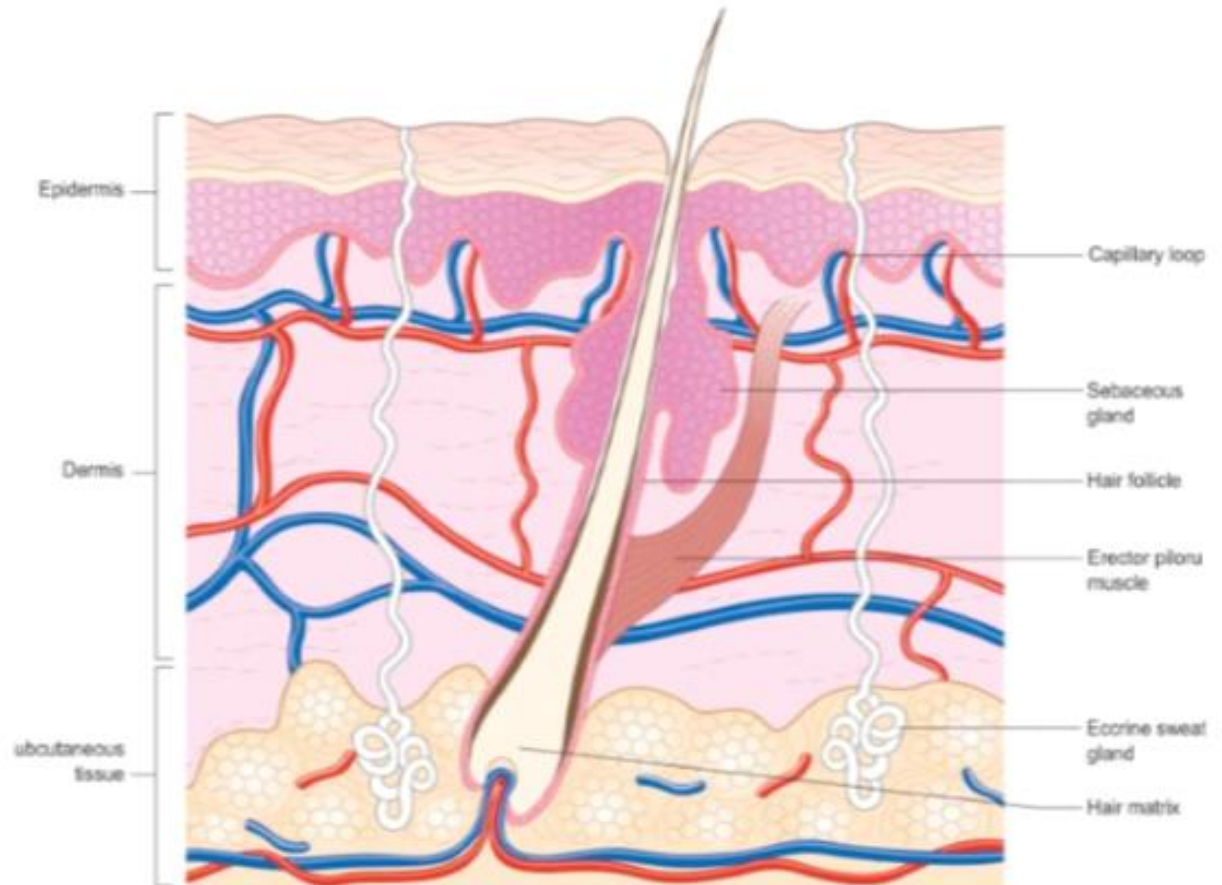


Skin graft Plastic Surgery: Volume 1: Principles. Scherer-Pietramaggiore, Saja S.; Pietramaggiore, Giorgio; Orgill, Dennis P.... Published January 1, 2018. Pages 214-230.e2. © 2018. My Athens/ clinical key



Hair

- Hair
 - Columns of dead keratinized epidermal cells

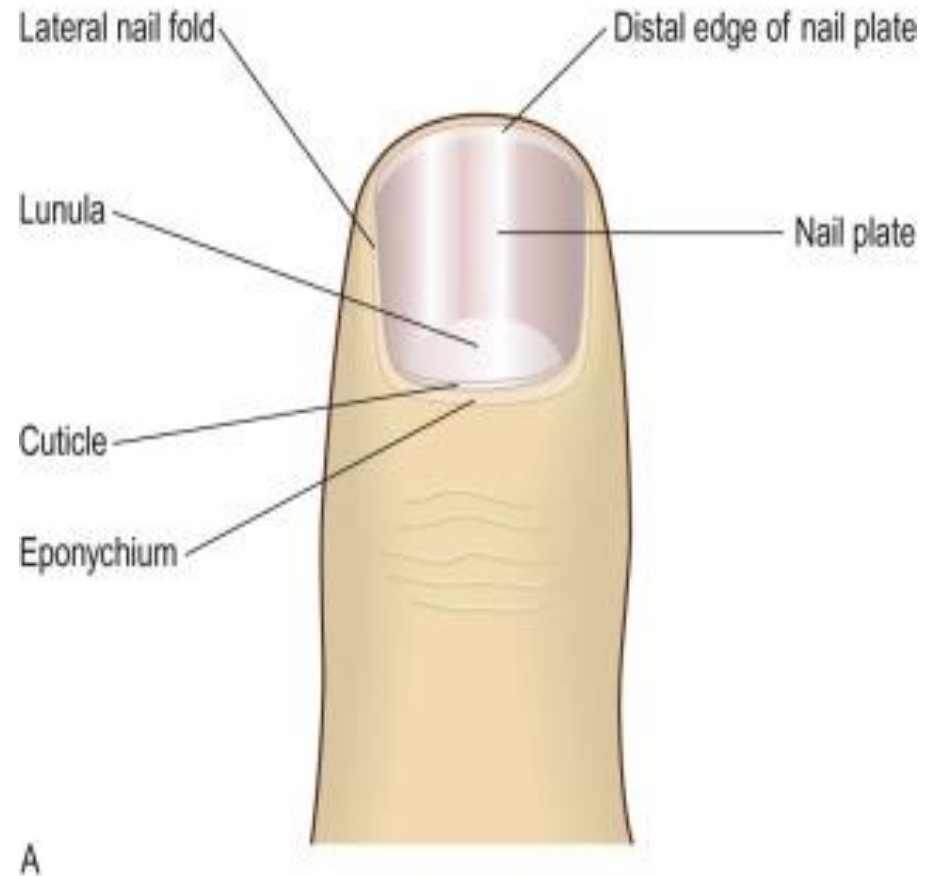


Skin, nails and hair Hutchison's Clinical Methods: An Integrated Approach to Clinical Practice. Cerio, Rino... Published January 1, 2012. Pages 333-347. © 2012. Figure 15.1. My Athens/ Clinical Key



Nails

- Nails
 - Plates of tightly packed, hard, dead, keratinized epidermal cells

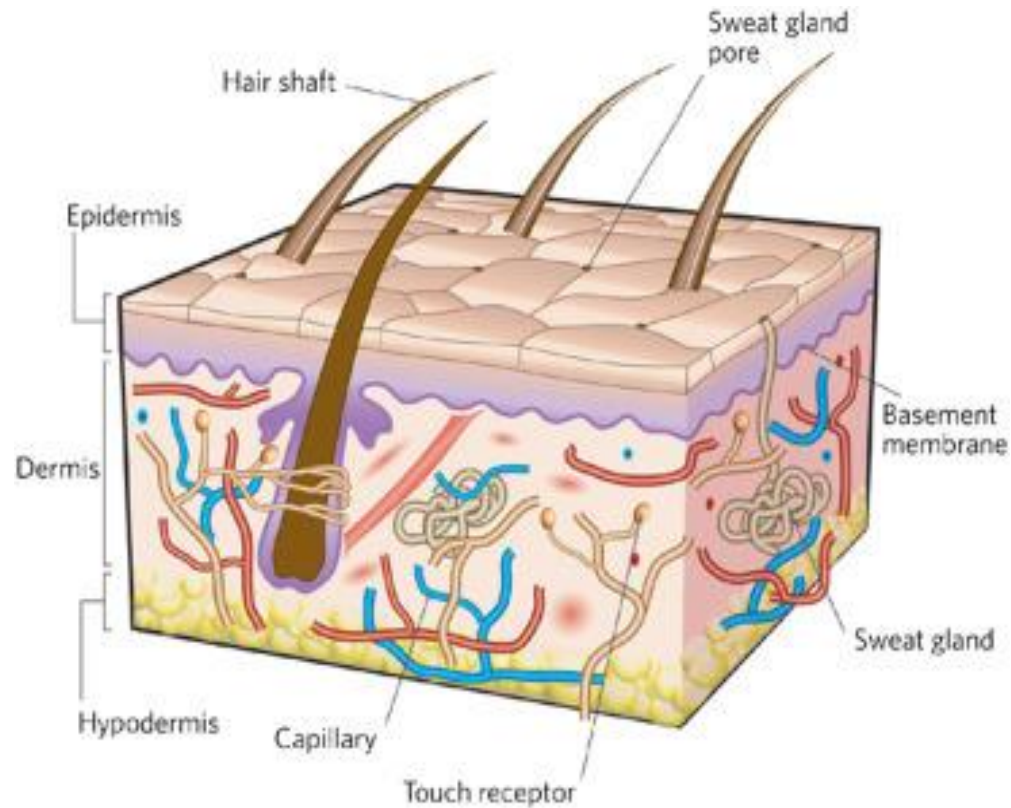


The skin, hair and nails Macleod's Clinical Examination. Gawkrödger, David... Published January 1, 2013. Pages 63-76. © 2013. Fig. 4.2. My Athens/ Clinical Key



Functions of the Skin

- Thermoregulation
- Blood Reservoir
- Protection
- Cutaneous Sensation
- Excretion and Absorption
- Synthesis of Vitamin D

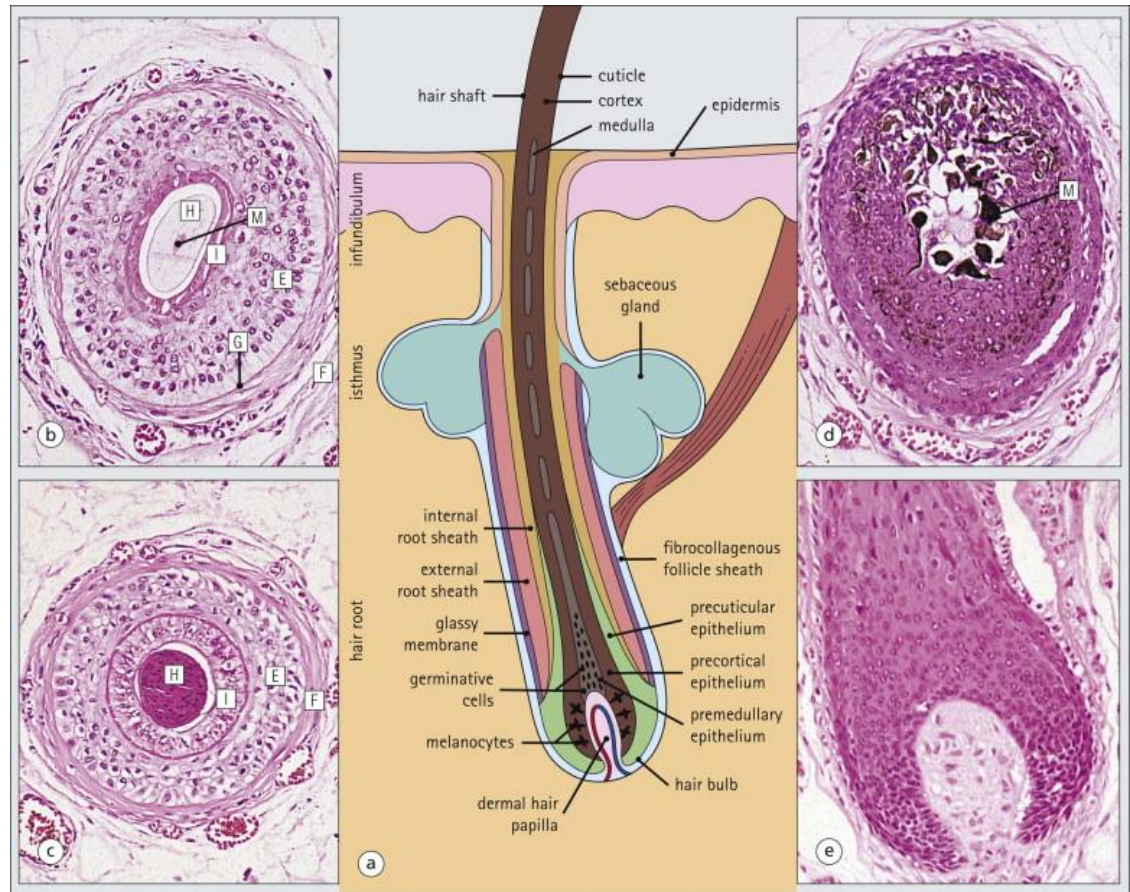


Characterization and Management of Dermatologic Adverse Events With the NovoTTF-100A System, a Novel Anti-mitotic Electric Field Device for the Treatment of Recurrent Glioblastoma Seminars in Oncology. Lacouture, Mario E.; Elizabeth Davis, Mary; Elzinga, Grace... Show all... Published June 1, 2014. Volume 41, Supplement 4. Pages S1-S14. © 2014. Figure 3. My Athens/ Clinical Key



Functions of the Sebaceous Glands

- Secrete an oily substance called sebum

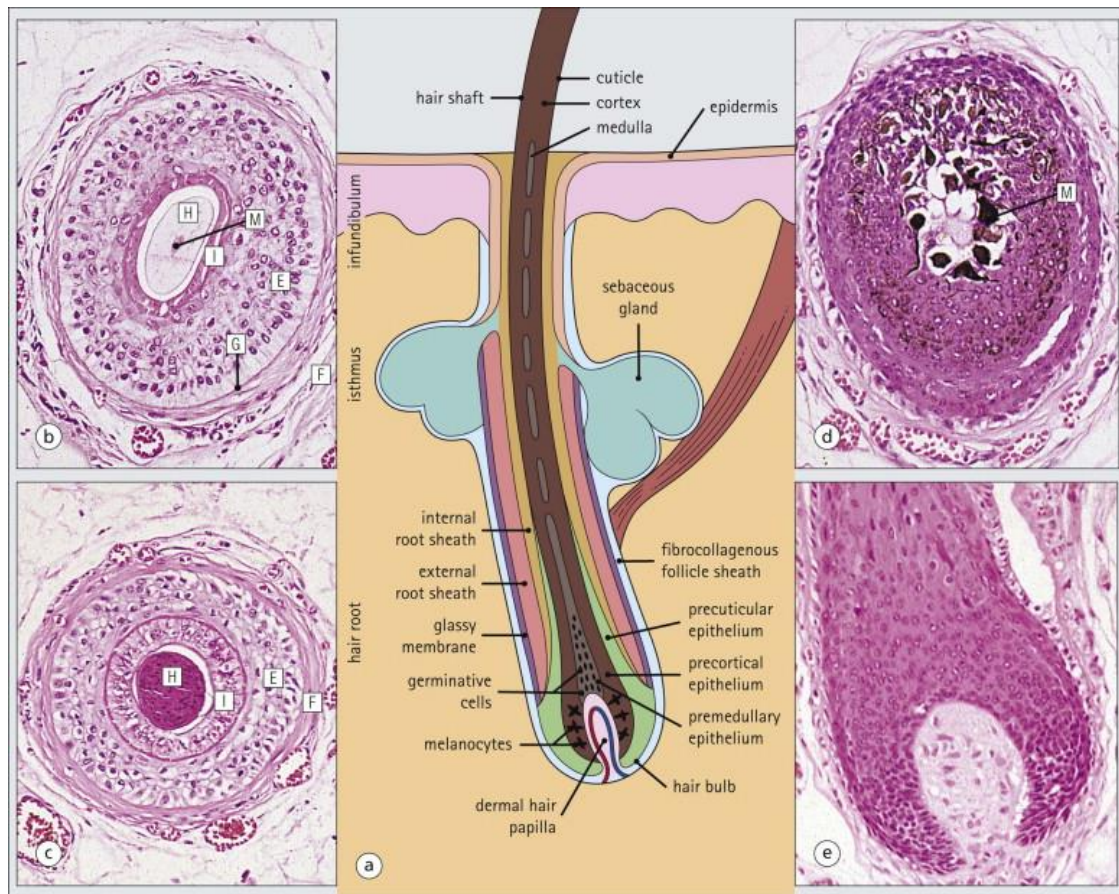


Skin and Breast Stevens & Lowe's Human Histology. Lowe, James S., BMedSci, BMBS, DM, FRCPath; Anderson, Peter G., DVM, PhD... Published January 1, 2015. Pages 363-384. © 2015. FIGURE 18.12. My Athens/ Clinical Key



Functions of the Sweat Glands

- Regulate body temperature through evaporation

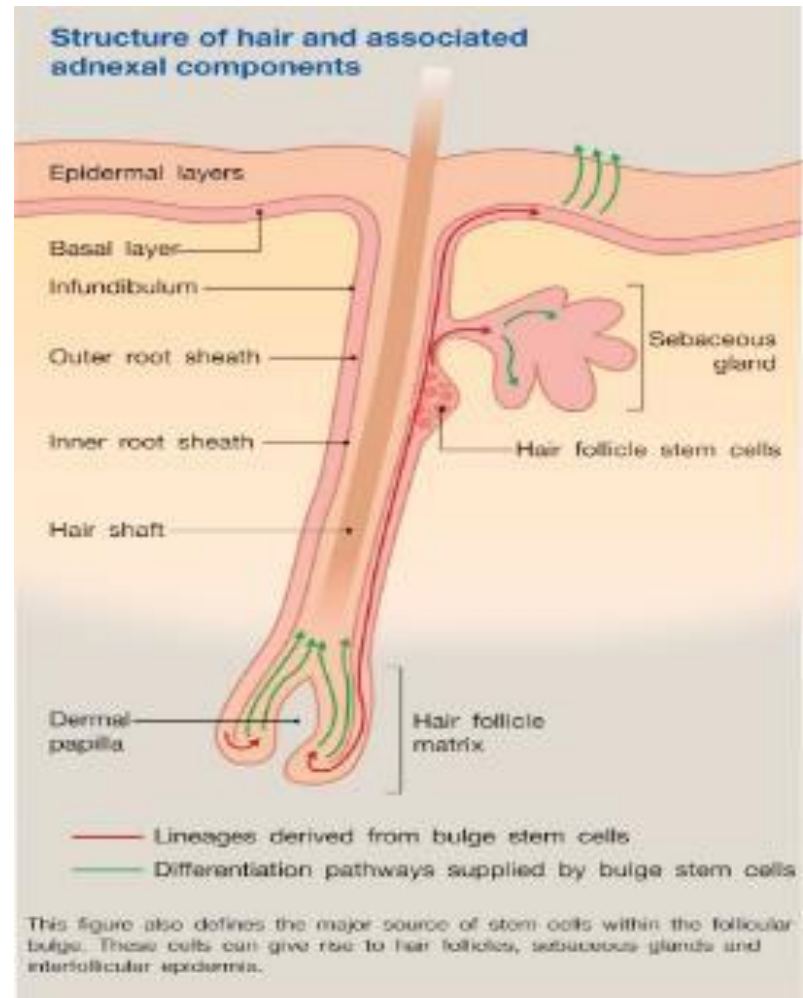


Skin and Breast Stevens & Lowe's Human Histology. Lowe, James S., BMedSci, BMBS, DM, FRCPath; Anderson, Peter G., DVM, PhD... Published January 1, 2015. Pages 363-384. © 2015. FIGURE 18.12. My Athens/ Clinical Key



Functions of Hair

- Provides protection and decrease heat loss



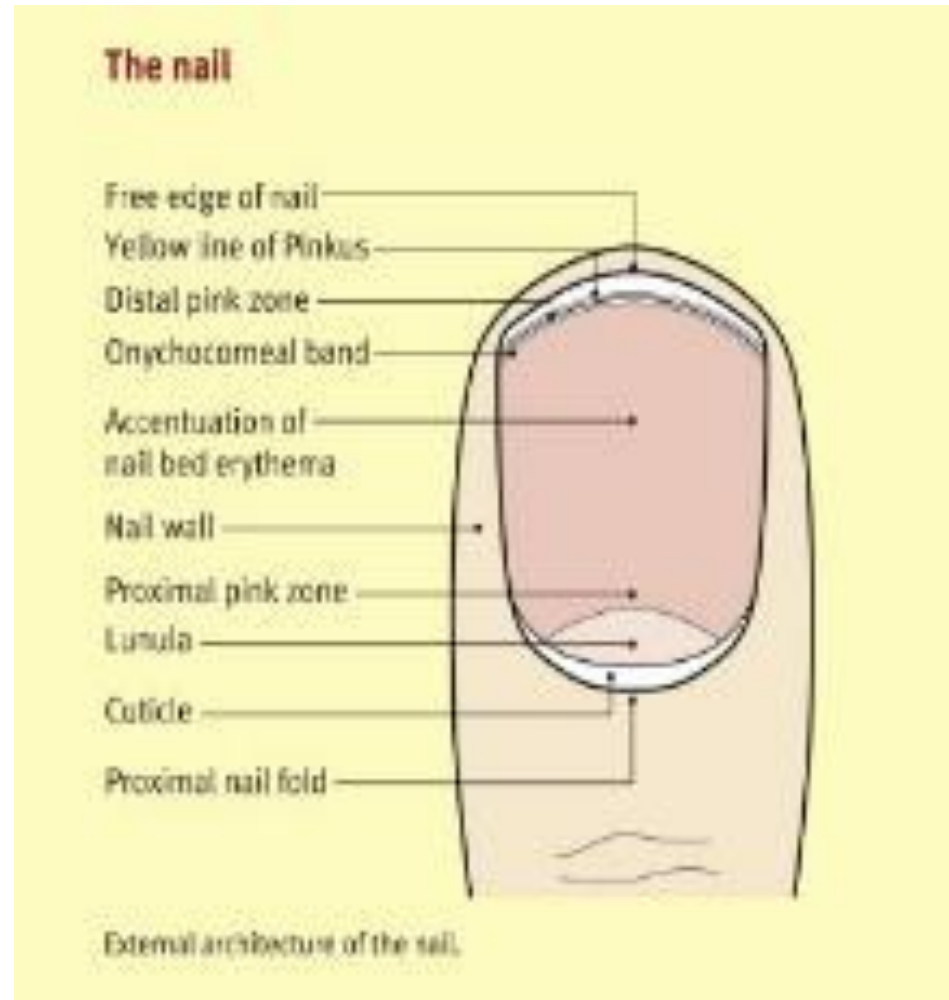Structure and function of skin, hair and nails
Medicine. Lai-Cheong, Joey E.; McGrath,
John A.... Published June 1, 2017. Volume
45, Issue 6. Pages 347-351. © 2017. Figure
4. My Athens/ Clinical Key



Functions of Nails

- Protects the distal end of the digits

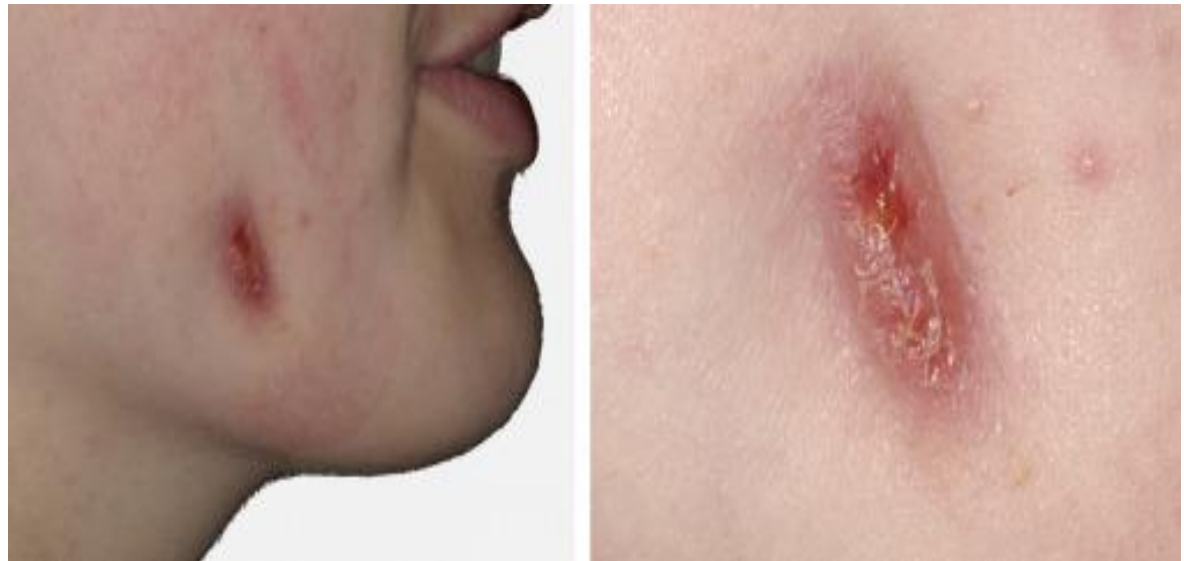Structure and function of skin, hair and nails Medicine.Lai-Cheong, Joey E.; McGrath, John A.... Published May 1, 2009. Volume 37, Issue 5. Pages 223-226. © 2009. Figure 4. My Athens/Clinical Key





Cutaneous Lesions

- Identified based upon clinical appearance
- Biopsy is necessary for definitive diagnosis.

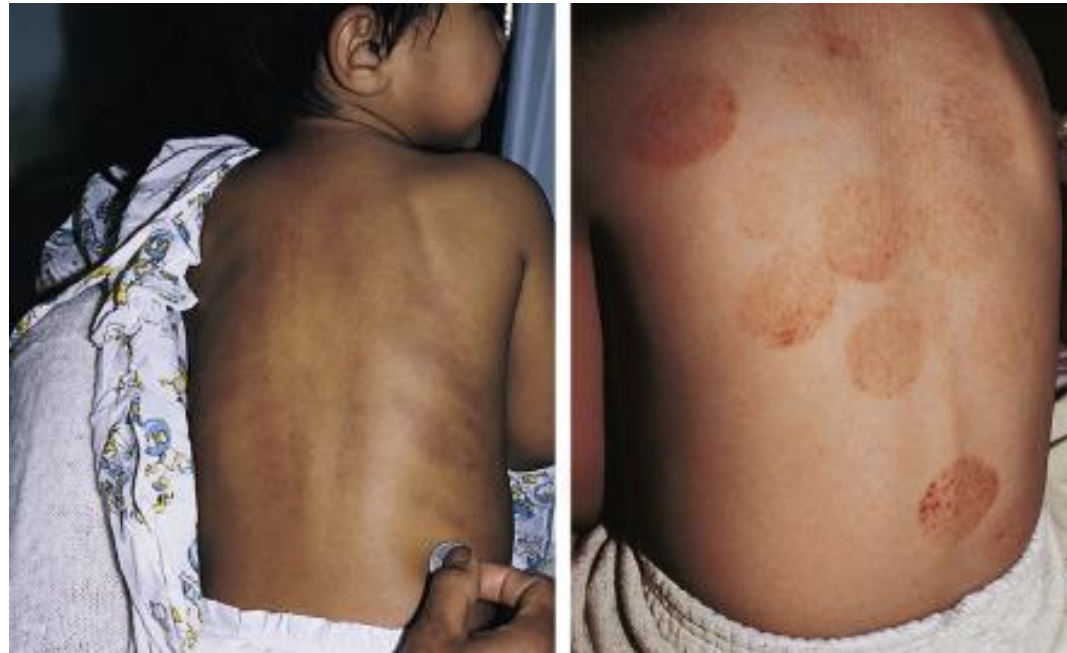

Treatment of a Crohn's disease–related cutaneous facial lesion with topical tacrolimus Oral Surgery, Oral Medicine, Oral Pathology and Oral Radiology. Shah, Neha P., BDS; Goel, Rishi M., MBBS,... Show all. Published September 1, 2014. Volume 118, Issue 3. Pages e71-e73. © 2014. Fig. 1. My Athens/ Clinical Keys



Lesion Evaluation

- Irregularities should be evaluated for:
 - A- Asymmetry
 - B- Borders
 - C- Color
 - D- Diameter
 - E- Evolution over time

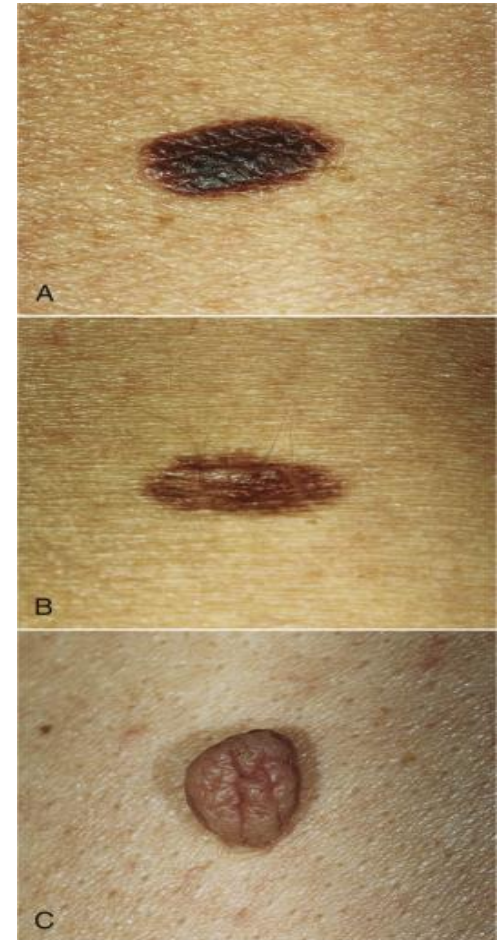


Seidel's Guide to Physical Examination.. Published December 31, 2018. Pages 131-183. © 2019. My Athens/ Clinical Key



Skin Lesion Description

- Good description includes:
 - Number
 - Size
 - Color
 - Shape
 - Texture
 - Primary lesion
 - Location
 - Configuration



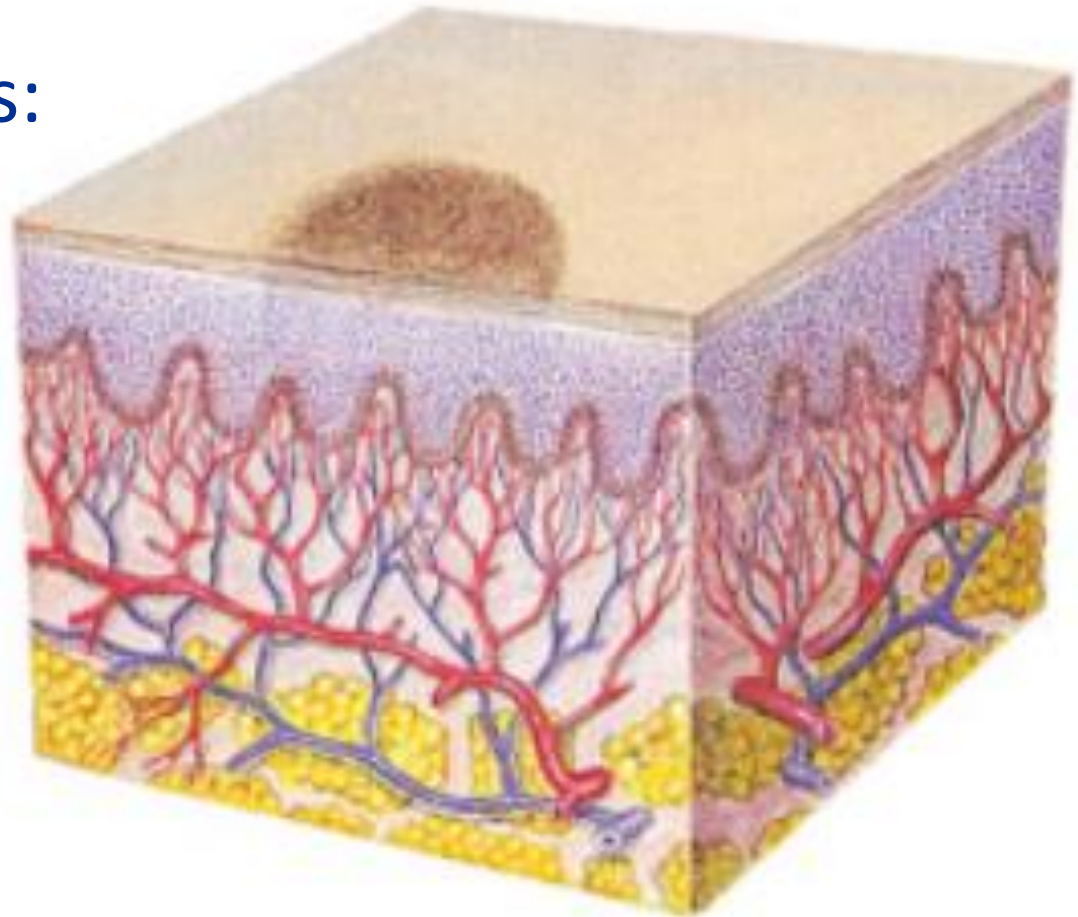
Seidel's Guide to Physical Examination. Published January 1, 2019. Pages 131-183. © 2019. My Athens/ Clinical Key



Primary Lesions

Describing Findings:

- Primary Lesion
 - Flat
 - Macule
 - Patch



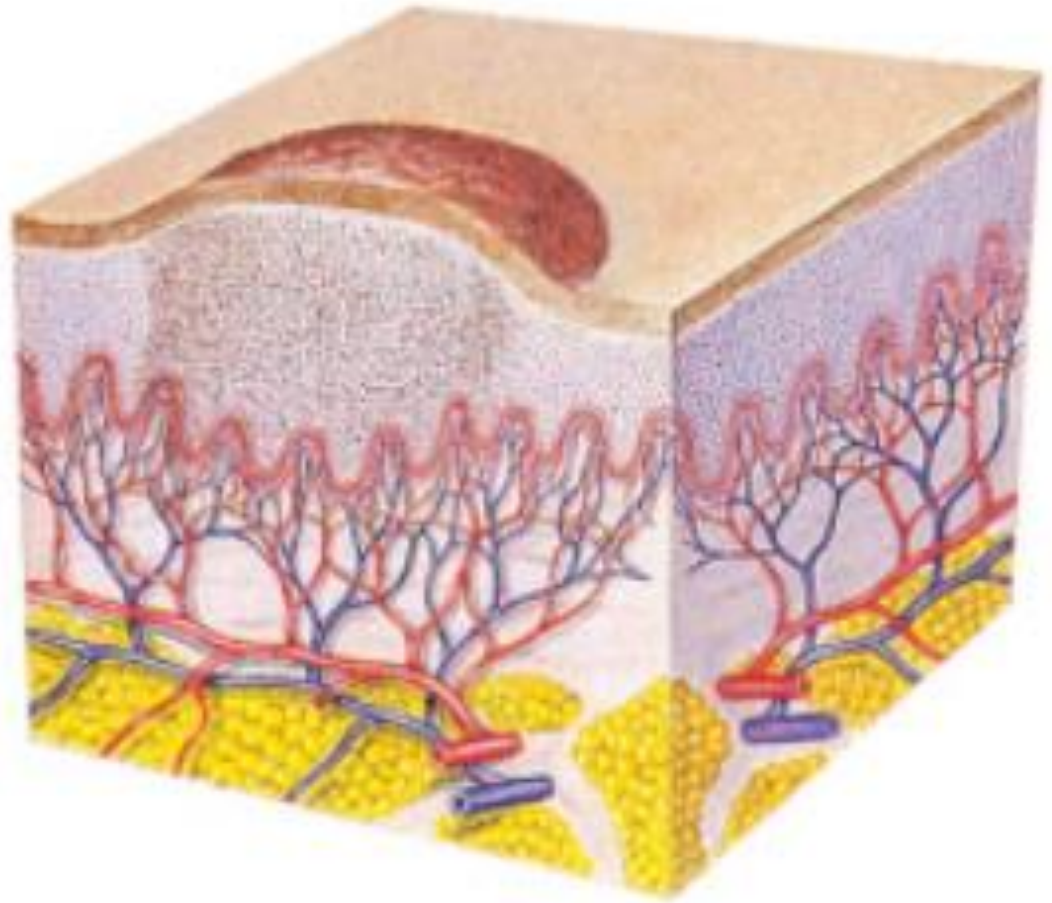
Seidel's Guide to Physical Examination. Published January 1, 2019. Pages 131-183. © 2019. Lichen planus. My Athens/ Clinical Key.



Primary Lesions (Cont.)

Describing Findings:

- Primary Lesion
 - Raised
 - Papule
 - Plaque
 - Vesicle
 - Bulla



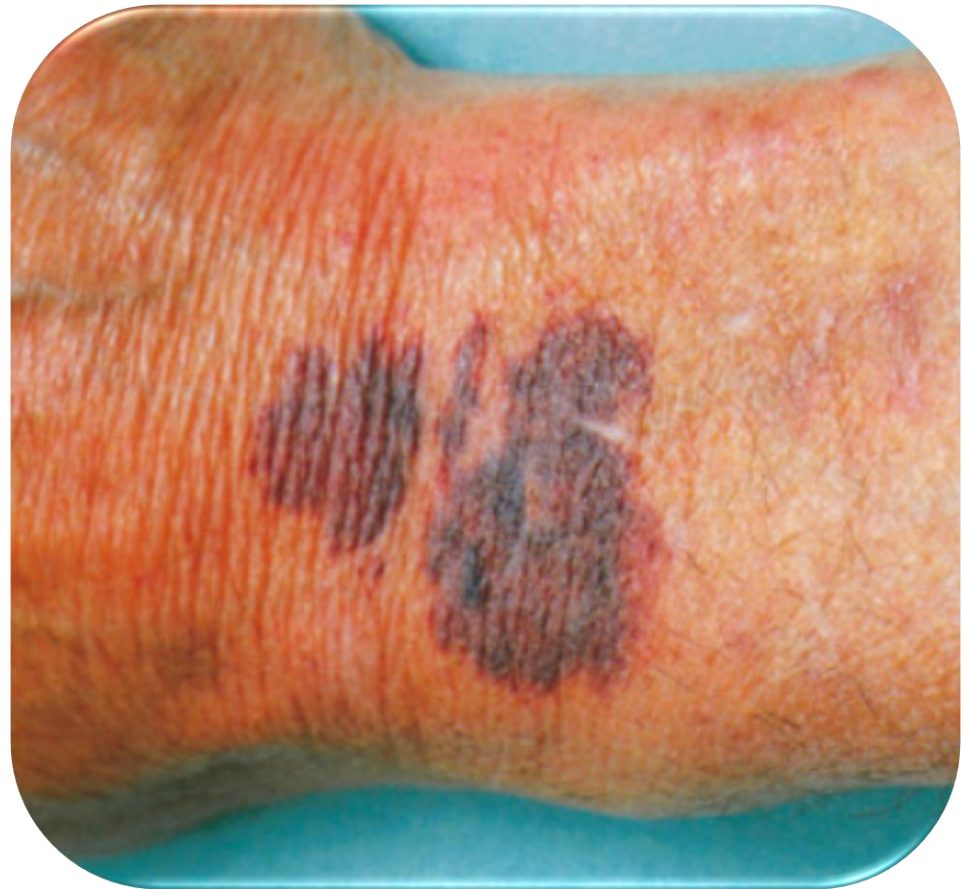Seidel's Guide to Physical Examination. Published January 1, 2019. Pages 131-183. © 2019. Lichen planus. My Athens/ Clinical Key.



Number of Lesions

Describing Findings:

- Number
 - Solitary or multiple
 - If multiple, record how many



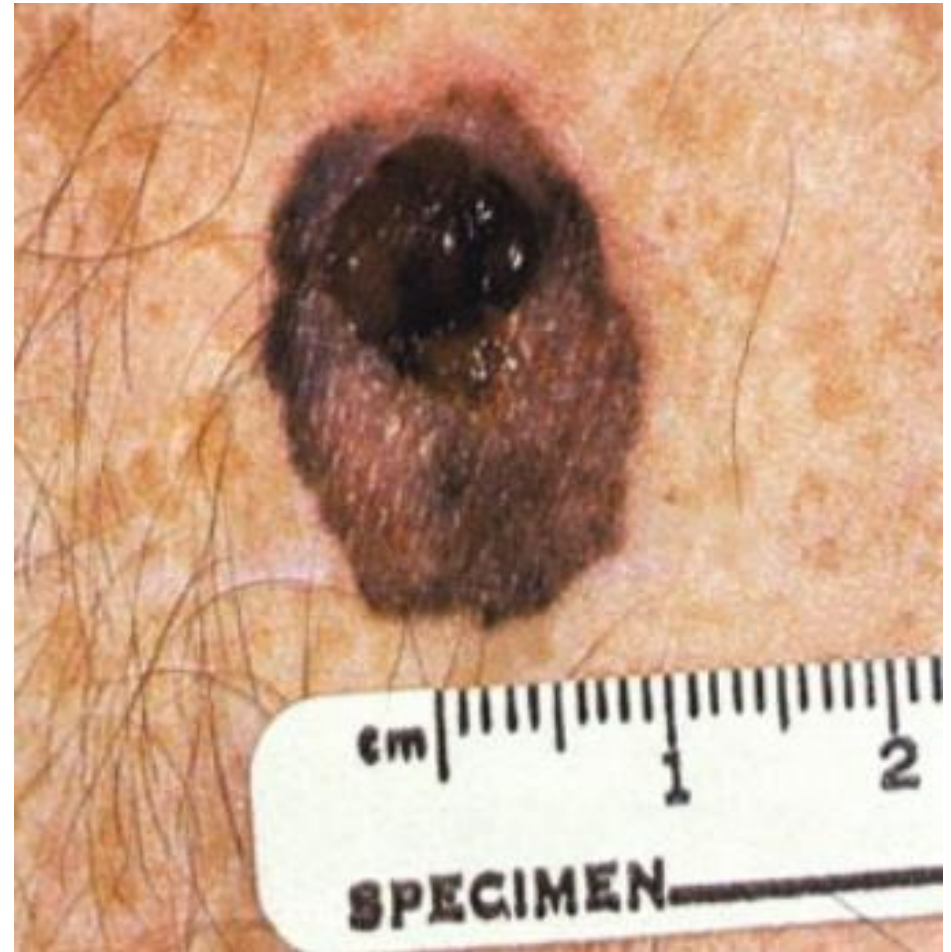Seidel's Guide to Physical Examination. Published January 1, 2019. Pages 131-183. © 2019. FIG. 9.8 (From Hoffbrand et al, 2010 .) Senile purpura. My Athens/ Clinical Key



Size

Describing Findings:

- Size
 - Measure with ruler
 - Millimeters or Centimeters



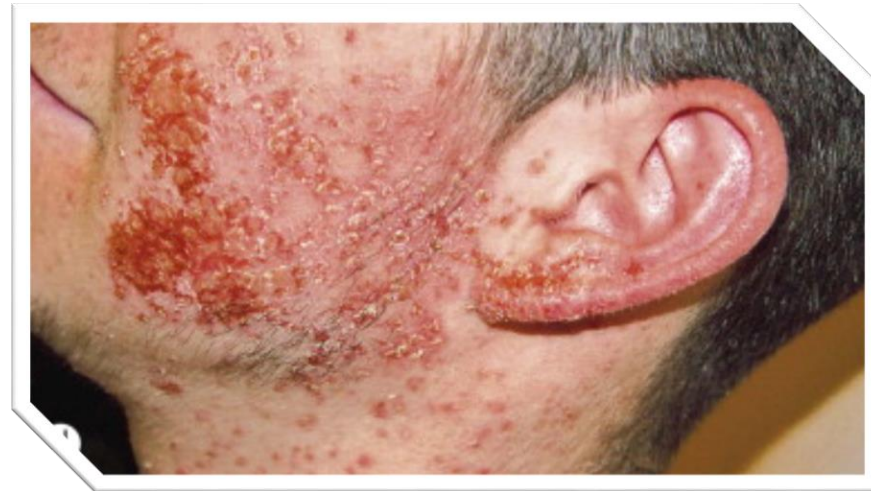Seidel's Guide to Physical Examination. Published January 1, 2019. Pages 131-183. © 2019. FIG. 9.60 (From the Centers for Disease Control and Prevention/Carl Washington, MD, Emory University School of Medicine; Mona Saraiya, MD, MPH.) Malignant melanoma. My Athens/ Clinical Key



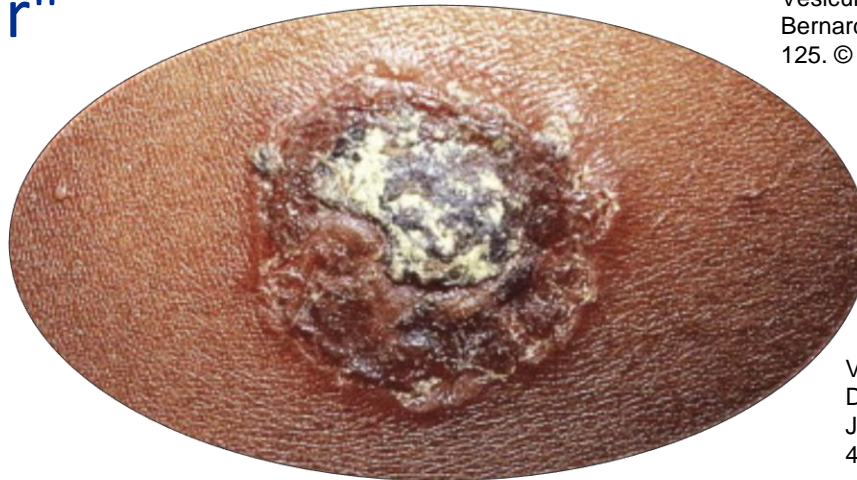
Shape

Describing Findings:

- Shape
 - Examples are "circular," "oval," "annular"



Vesiculopustular Eruptions Pediatric Dermatology. Cohen, Bernard A.... Published January 2, 2013. Pages 104-125. © 2013. Fig 4.12. My Athens/Clinical Key



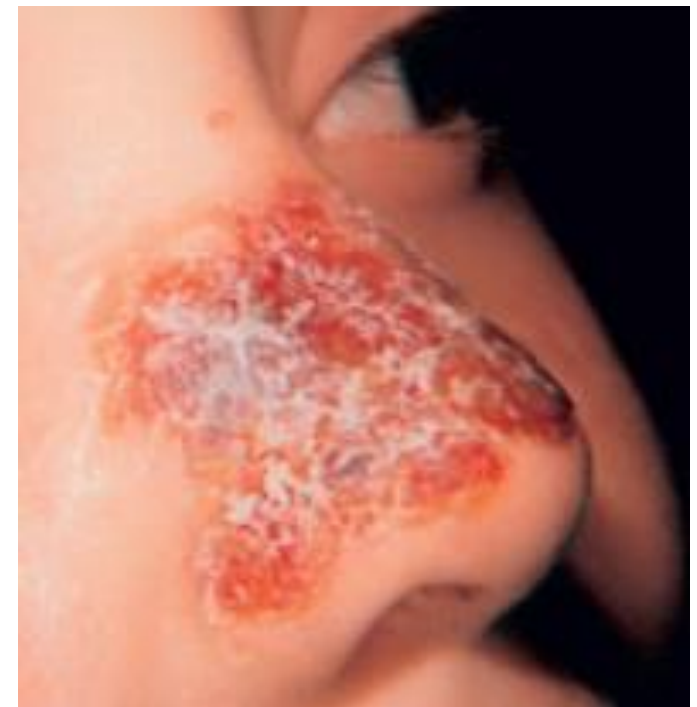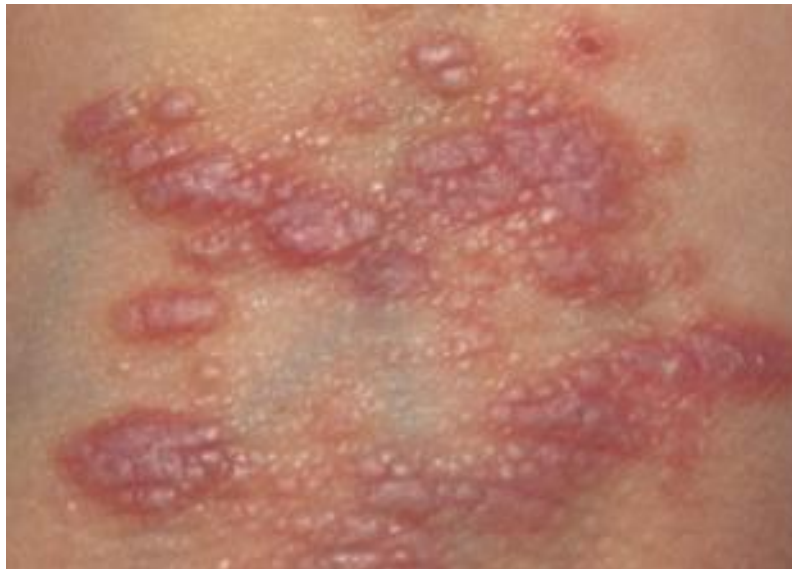Vesiculopustular Eruptions Pediatric Dermatology. Cohen, Bernard A.... Published January 2, 2013. Pages 104-125. © 2013. Fig 4.12. My Athens/ Clinical Key



Color

Describing Findings:

- Color
 - Refer to a color wheel



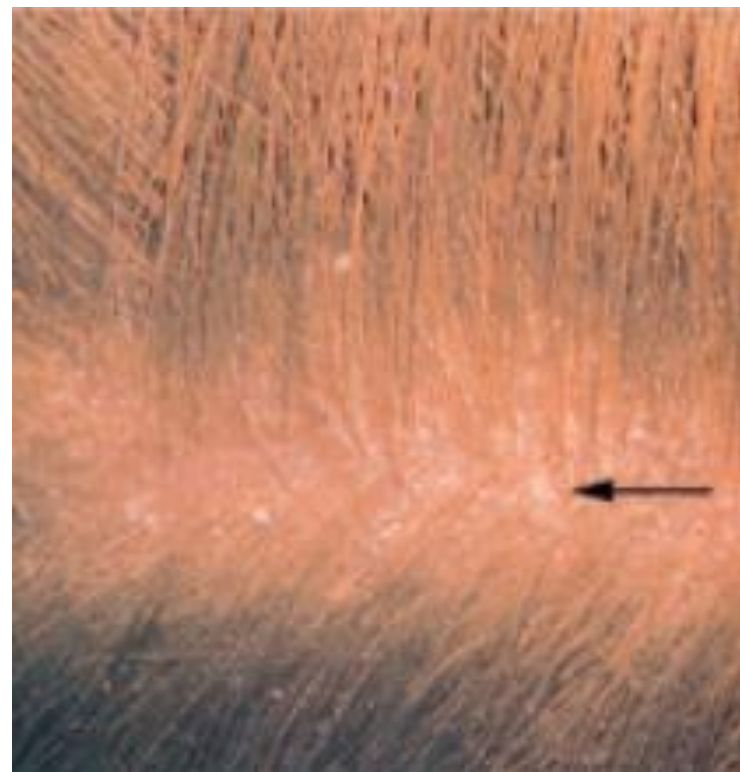
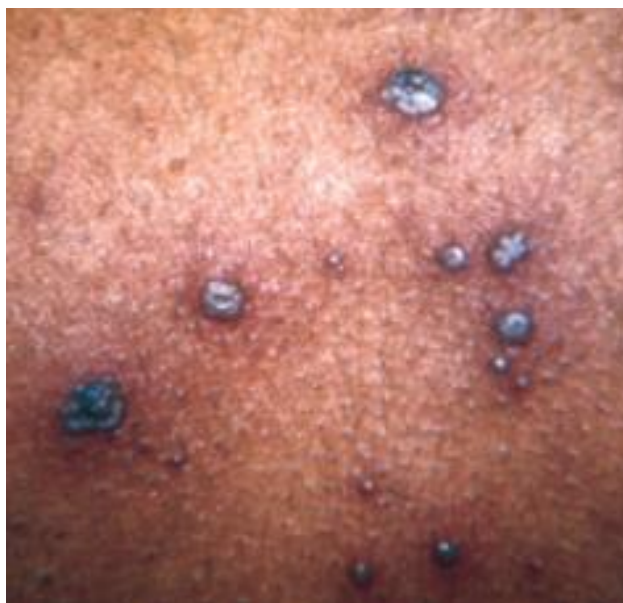Both images from Seidel's Guide to Physical Examination. Published January 1, 2019. Pages 131-183. © 2019. My Athens/ Clinical Key



Texture

Describing Findings:

- Texture
 - Palpate the lesion



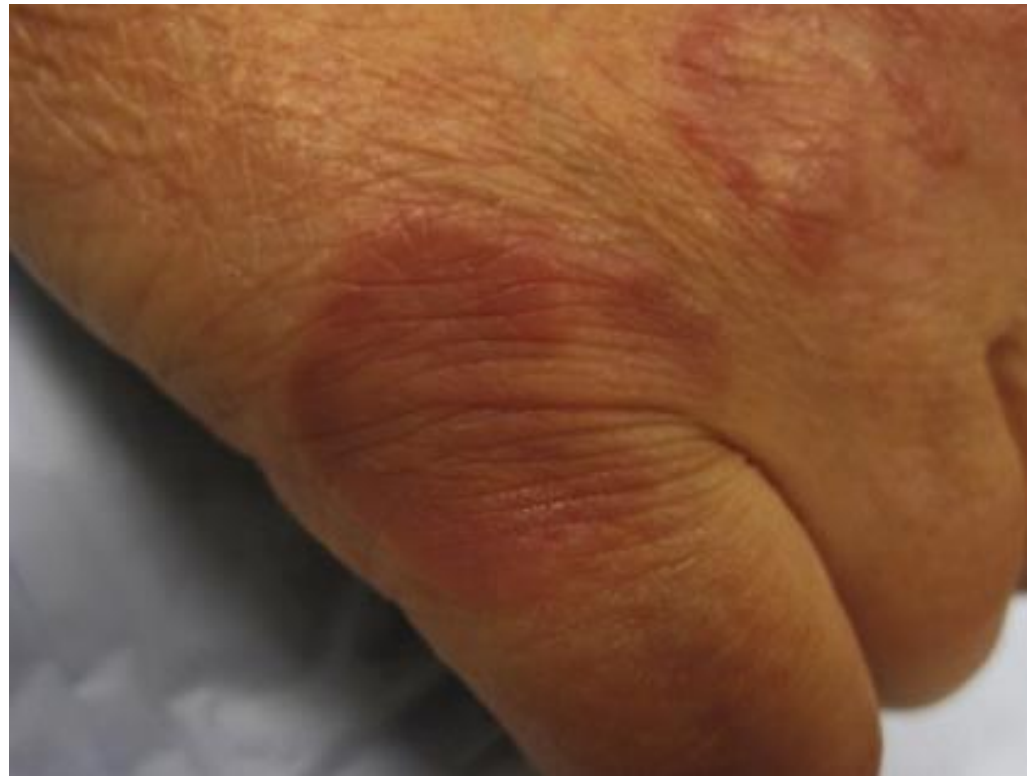Both images from Seidel's Guide to Physical Examination. Published January 1, 2019. Pages 131-183. © 2019. My Athens/ Clinical key



Location

Describing Findings:

- Location
 - For single lesions, measure their distance from other landmarks



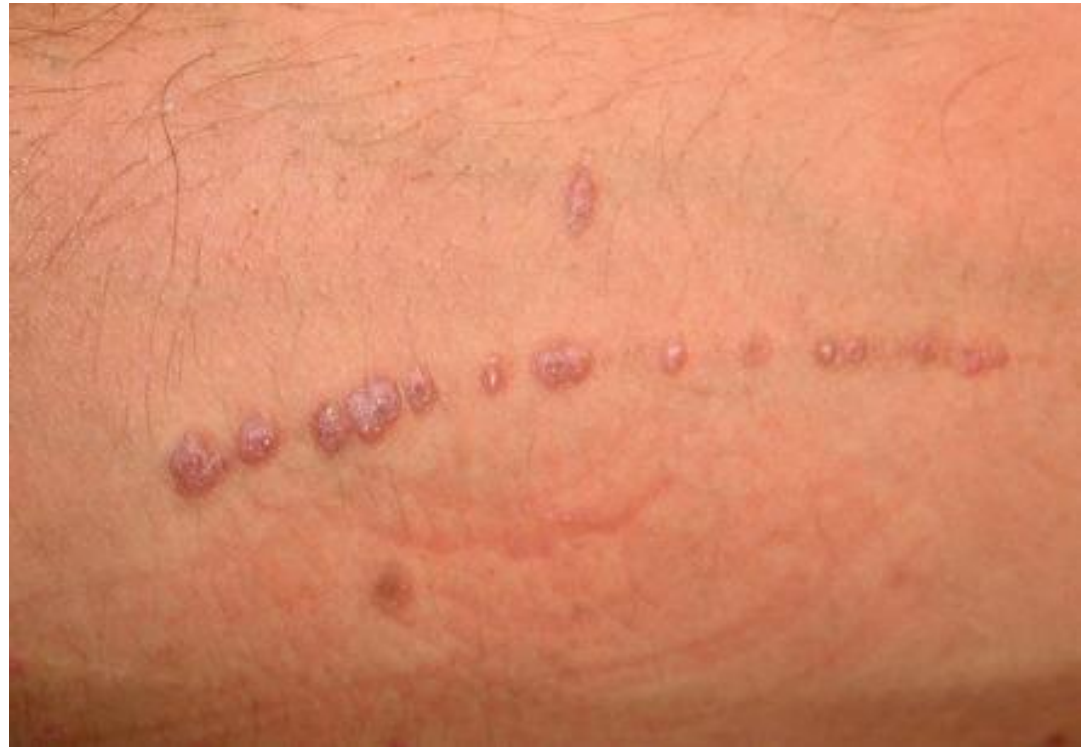Seidel's Guide to Physical Examination. Published January 1, 2019. Pages 131-183. © 2019. FIG. 9.14 (From Keimig, 2015 .) Annular formation of lesions (granuloma annulare). My Athens/ Clinical Key



Configuration

Describing Findings:

- Configuration
 - Describing patterns is often very helpful

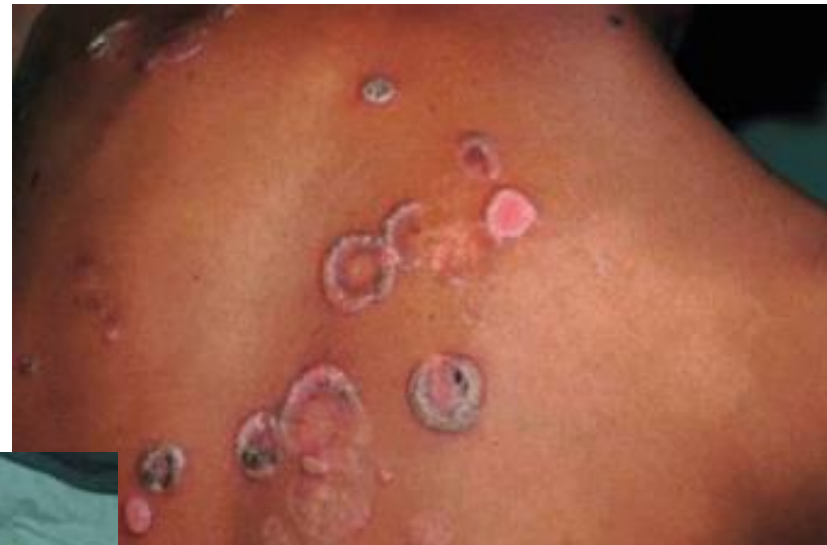
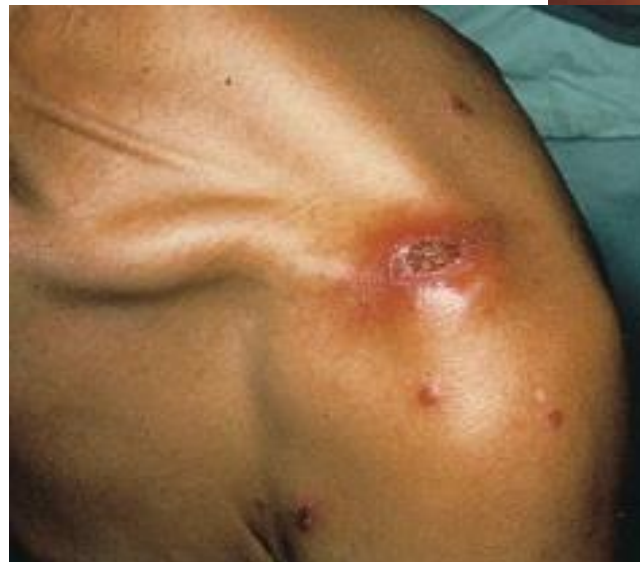
Basic Principles of Dermatology Dermatology. High, Whitney A.; Tomasini, Carlo Francesco;... Show all. Published January 1, 2018. Pages 1-43. © 2018. Fig. 0.10. My Athens/ Clinical Keys



Secondary Lesions

- Scales
- Crusts
- Excoriations
- Erosion
- Ulcer
- Scar
- Fissure

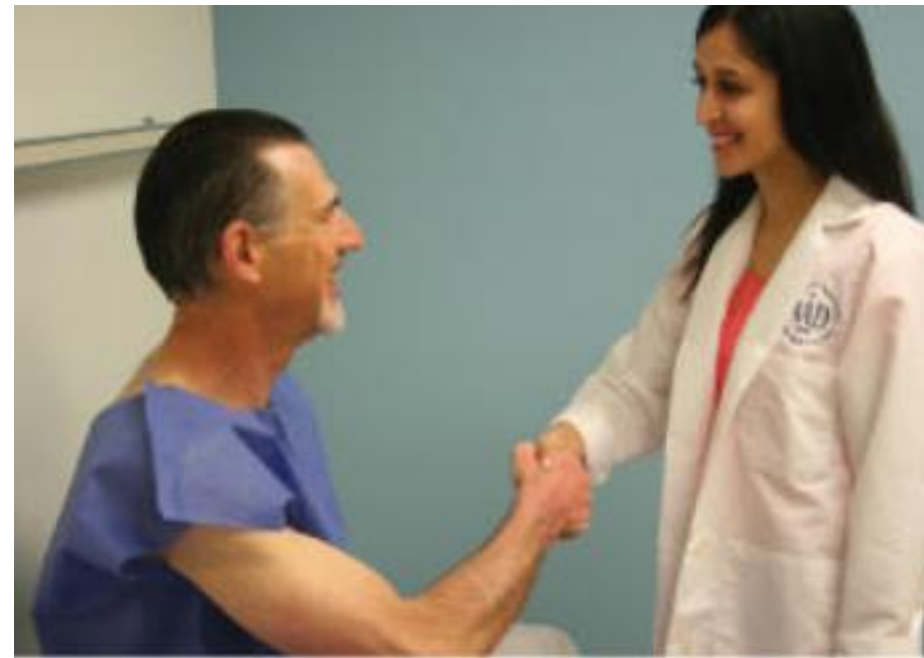

Both images from Syphilis, Yaws, Bejel, and Pinta
Andrews' Diseases of the Skin. James, William D., MD;
Berger, Timothy G.,... Show all. Published January 1,
2016. Pages 343-358.e3. © 2016. Fig. 18-3.



History

- Subjective includes:
 - CC
 - HPI
 - PMH
 - Family History
 - Personal and Social History
 - Review of Systems



Bates guide to physical examination and history taking [12th ed.]. Philadelphia, PA.) My Athens/ STAT!Ref



History of Present Illness

- Changes in skin
- Changes to lesions
- Onset
- Location
- Duration
- Characteristics
- Exposure to environment, travel, people
- What makes it better or worse
- Treatments tried



Past Med Hx

- Previous skin problems
- Sensitivities to light and touch
- Loss, growth or thinning of hair
- Systemic disease
- Infections



Family Hx

- Dermatologic disorders or diseases
- Allergies
- Hair loss



Personal and Social Hx

- Skin care
- Hair care
- Nail care
- Tobacco
- Alcohol
- STIs



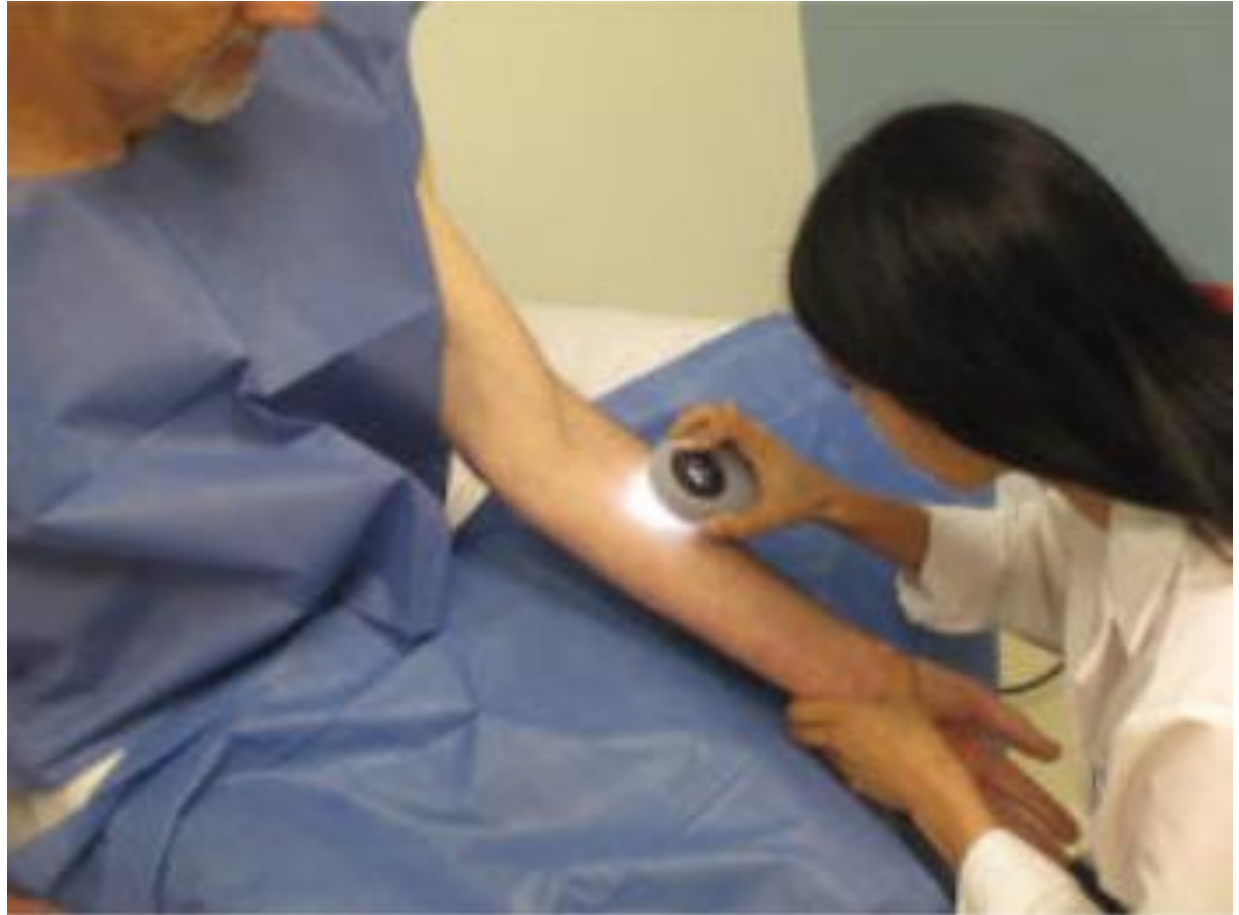Review of Systems

- Constitutional
- Cardio
- Gastro
- Blood/lymph
- Endocrine



Skin Examination

- Inspection
- Palpation



Bates guide to physical examination and history taking [12th ed.]. Philadelphia, PA.) My Athens/ STAT!Ref



Hair Examination

- Inspection
 - Scalp, face, neck, chest, back, arms, legs, pubic region
- Palpation
 - Texture
 - Dryness



Nail Examination

- Inspect
 - Color, length, shape, configuration, cleanliness and symmetry
- Palpate
 - Uniformity, thickness, hardness, softness and smoothness



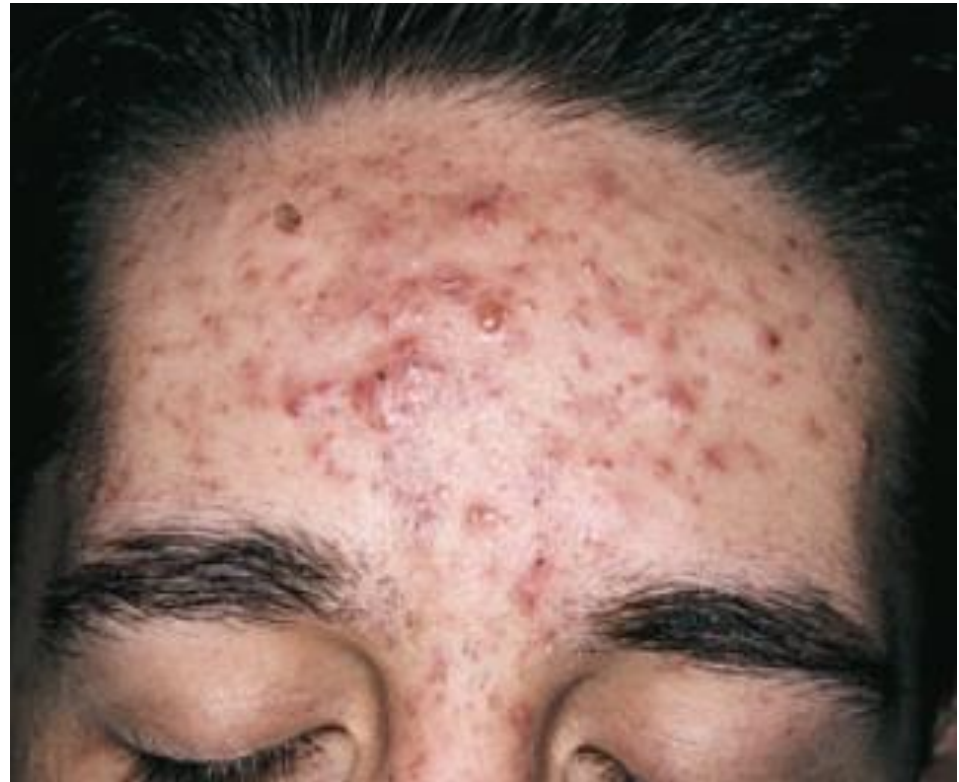Special Tests

- Woods Lamp Test
- Used to identify if a lesion is caused by a fungal infection
- Lesion will fluoresce if a fungus is present



Acne Vulgaris

- Signs and Symptoms
 - Mild Acne
 - Moderate Acne
 - Severe Acne

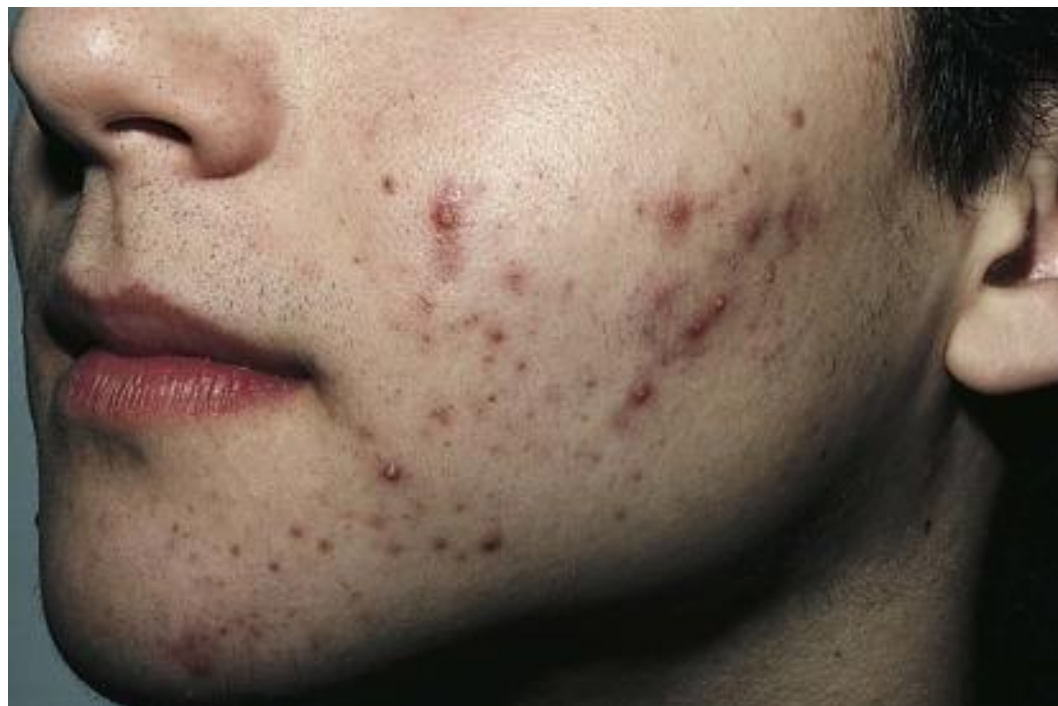

Seidel's Guide to Physical Examination. Published January 1, 2019. Pages 131-183.
© 2019. FIG. 9.79 (From Swartz, 2014 .) Acne in adolescent. My Athens/ Clinical key



Acne Plan

- Keep face clean and dry
- Mild Form
- Moderate Form
- Severe Form

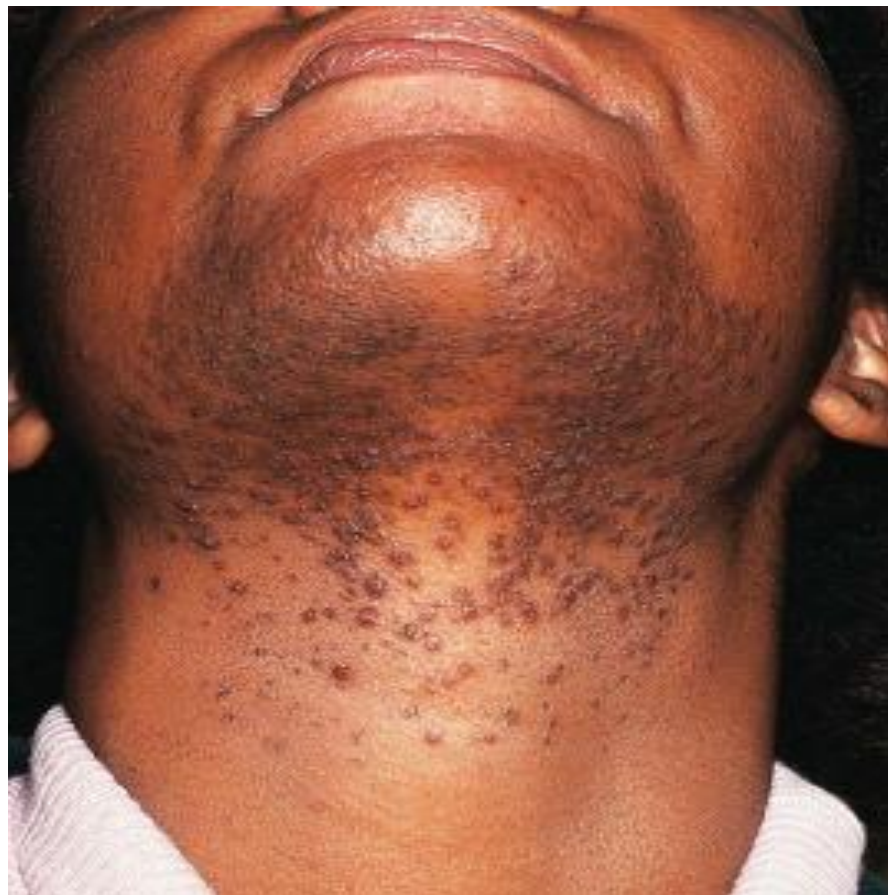


The Skin Textbook of Physical Diagnosis.
Swartz, Mark H., MD, FACP... Published
January 1, 2014. Pages 81-144.e1. © 2014.
Figure 5-77 Acne. My Athens/ Clinical Key



Folliculitis

- Folliculitis
- Furuncles
- Carbuncles

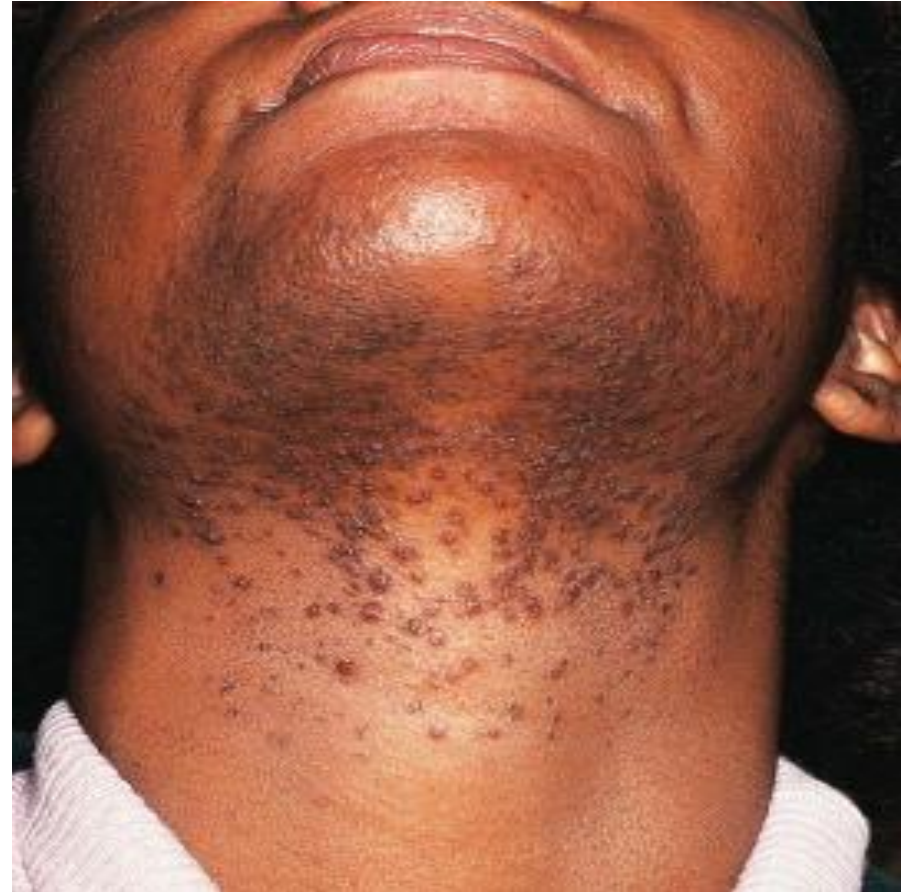


Folliculitis Dermatology Essentials. Published January 1, 2014. Pages 268-282. © 2014. Fig. 31.9 Courtesy, A. Paul Kelly, MD. Pseudofolliculitis barbae. Multiple firm hyperpigmented papules on the lower face and neck (beard distribution). My Athens/ Clinical Key



Folliculitis (Cont.)

- Signs and Symptoms
 - Folliculitis
 - Furuncles
 - Carbuncle

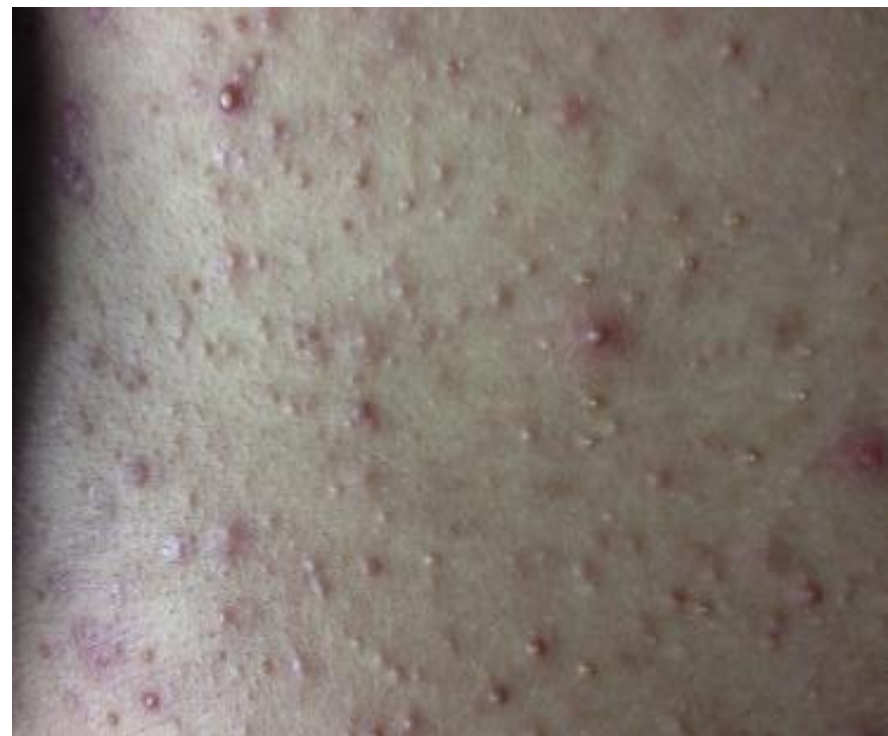

Folliculitis Dermatology Essentials. Published January 1, 2014. Pages 268-282. © 2014. Fig. 31.9 Courtesy, A. Paul Kelly, MD. Pseudofolliculitis barbae. Multiple firm hyperpigmented papules on the lower face and neck (beard distribution). My Athens/ Clinical Key



Folliculitis Plan

- Keep hands off the face
- Avoid squeezing lesions
- Immobilize area
- Avoid over manipulation
- Folliculitis
 - Antibiotics



Folliculitis Treatment of Skin Disease: Comprehensive Therapeutic Strategies. Chen, Chen "Mary"; Phelps, Robert G.... Published January 1, 2018. Pages 278-280. © 2018. My Athens/ Clinical Key



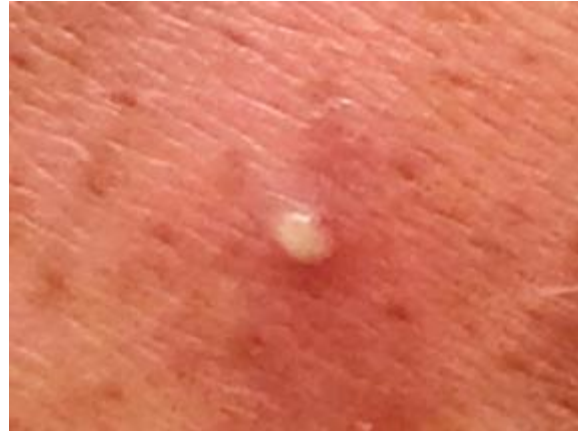Furuncle & Carbuncle Plan

- Furuncles

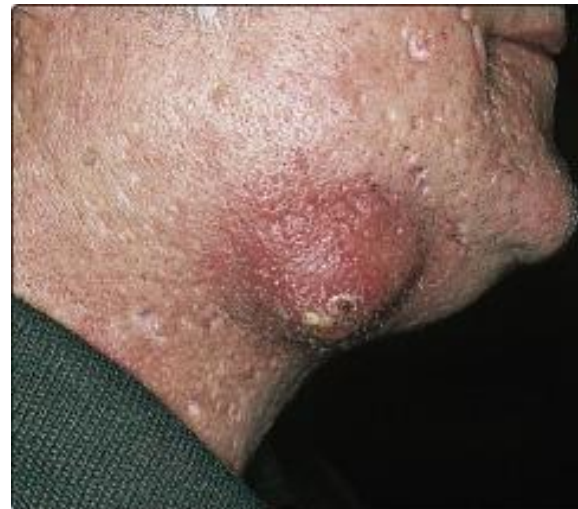- Hot compress
- May require I&D
- Antibiotics

- Carbuncles

- Hot compressed
- I&D if fluctuant
- Antibiotics



Skin and Soft Tissue Infections American Family Physician. Published September 15, 2015. Volume 92, Issue 6. Pages 474-483E. © 2015. Figure 3 Furuncle. My Athens/ Clinical Key

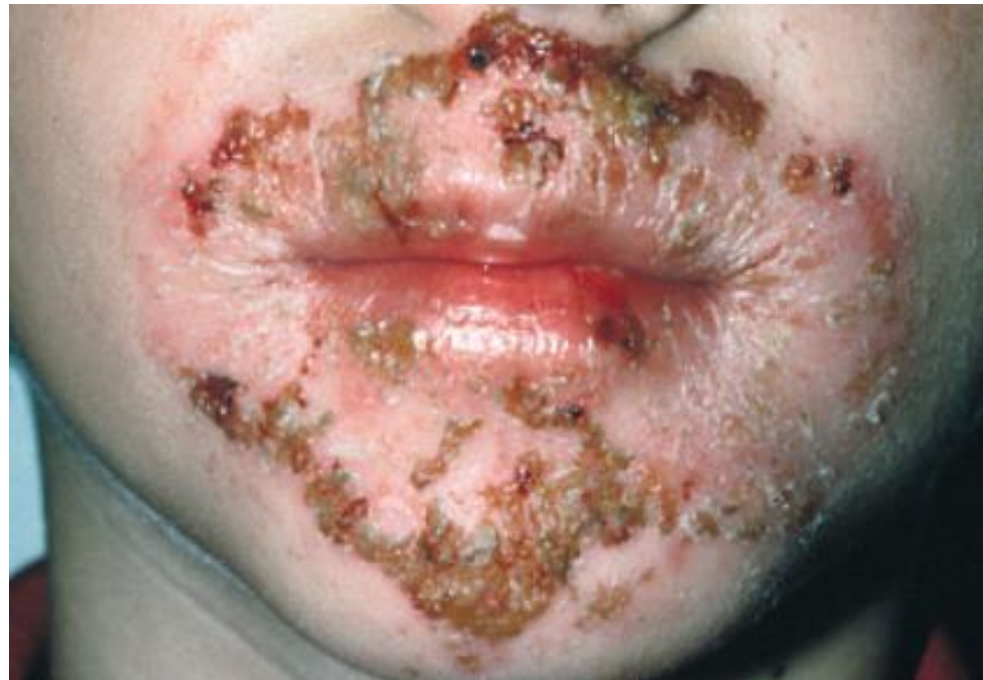

Bacterial infection – Staphylococcal and streptococcal Dermatology: An Illustrated Colour Text Published January 1, 2017. Pages 50-51. © 2017. Fig. 25.4 My Athens/ Clinical Key



Impetigo

- Signs and Symptoms
 - Starts as a small papule
 - Progresses into eroded vesicles
 - “Honey-colored crusted plaques” with erythematous base.

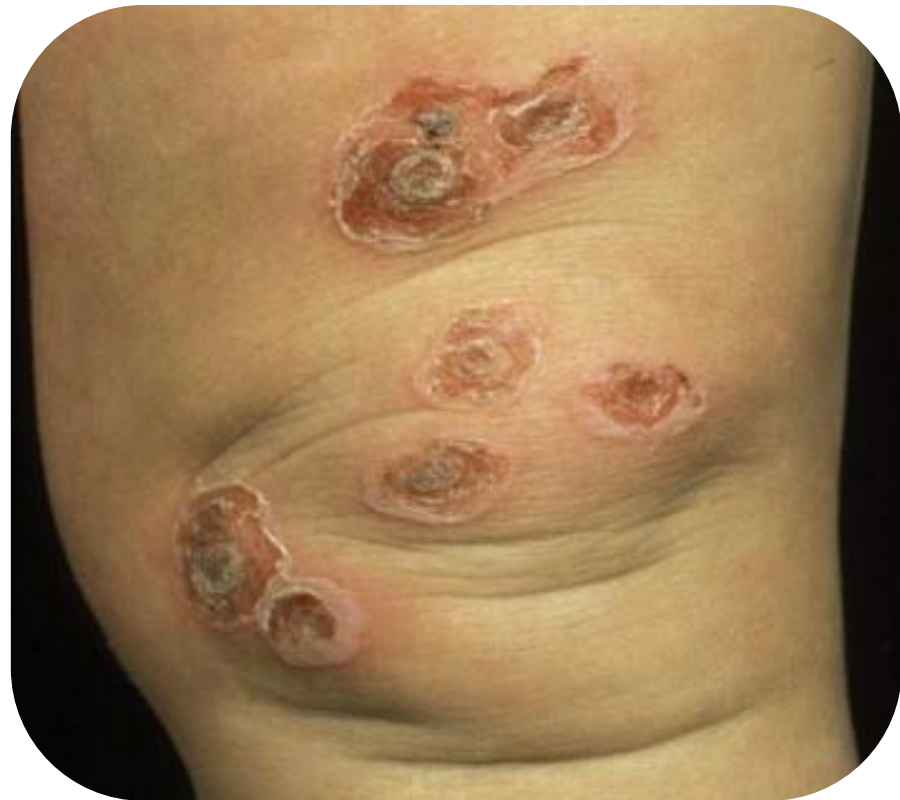

Bacterial Infections Oral and Maxillofacial Pathology. Published January 1, 2016. Pages 164-190. © 2016. Fig. 5-2 Impetigo.



Impetigo Plan

- Keep area clean and dry
- Antibiotics
- Refer to provider for isolation procedures



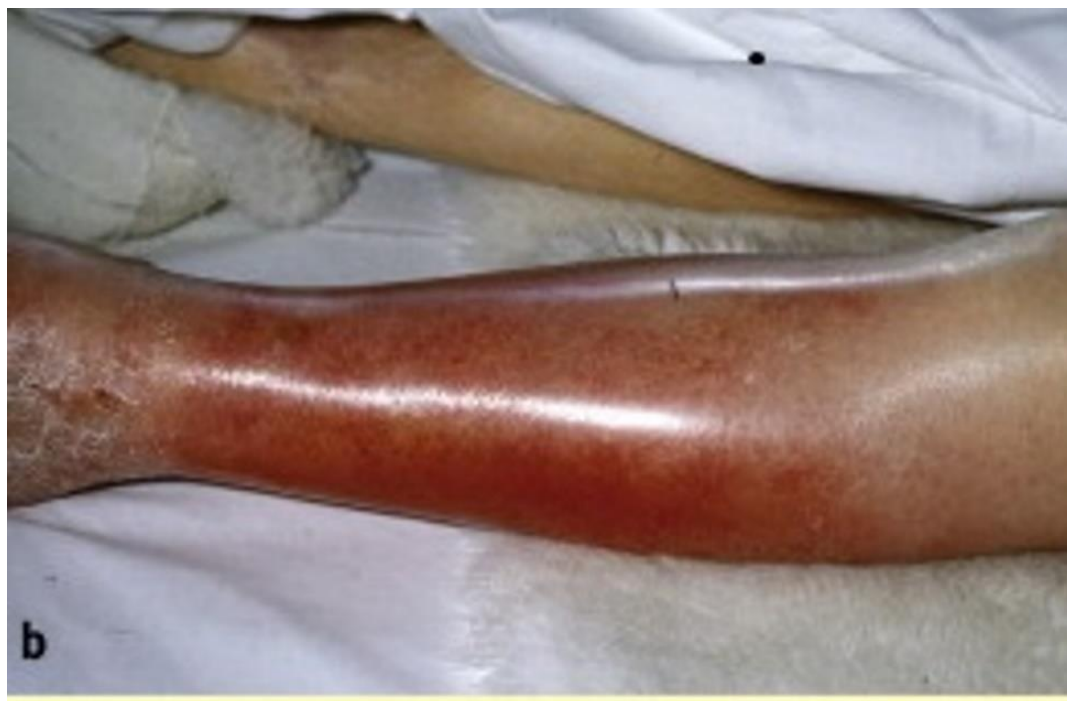Infections and infestations of the skin Paediatrics and Child Health. Goodyear, Helen... Published February 1, 2015. Volume 25, Issue 2. Pages 72-77. © 2014. Figure 1 Impetigo My Athens/ Clinical Key



Cellulitis

- Signs and Symptoms

- Large, well-defined area of erythema
- Edema and pain with touch
- The appearance and texture is that of an orange peel

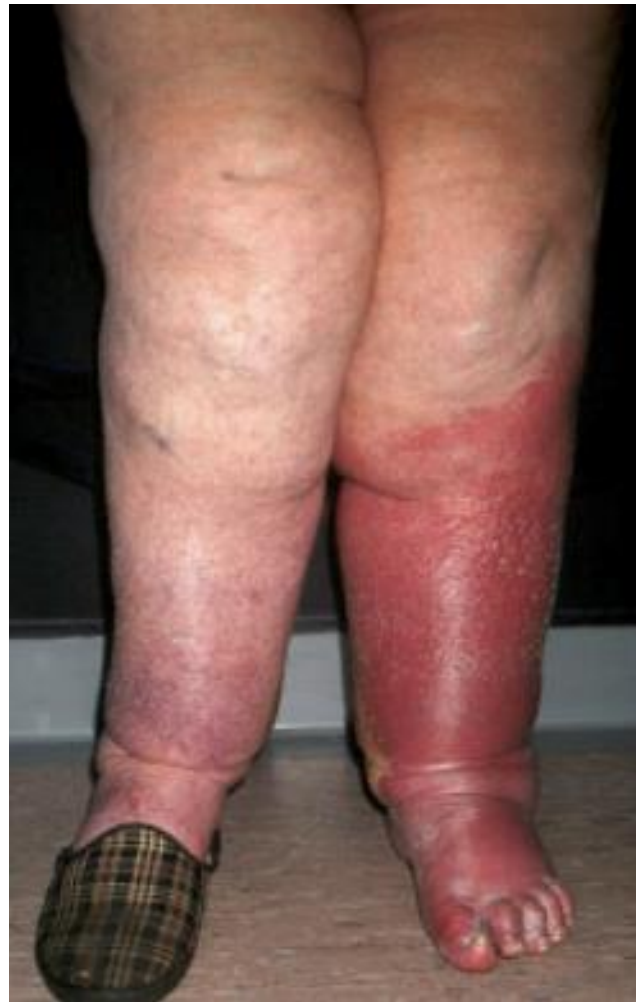

Cellulitis Clinical Overview. Published April 21, 2016. © 2017. 37(2):96-9, 2008, Figure 1B. My Athens/ Clinical Key



Cellulitis Plan

- Warm soaks, bed rest, keep affected area elevated
- Antibiotics
- Refer to provider for isolation procedures

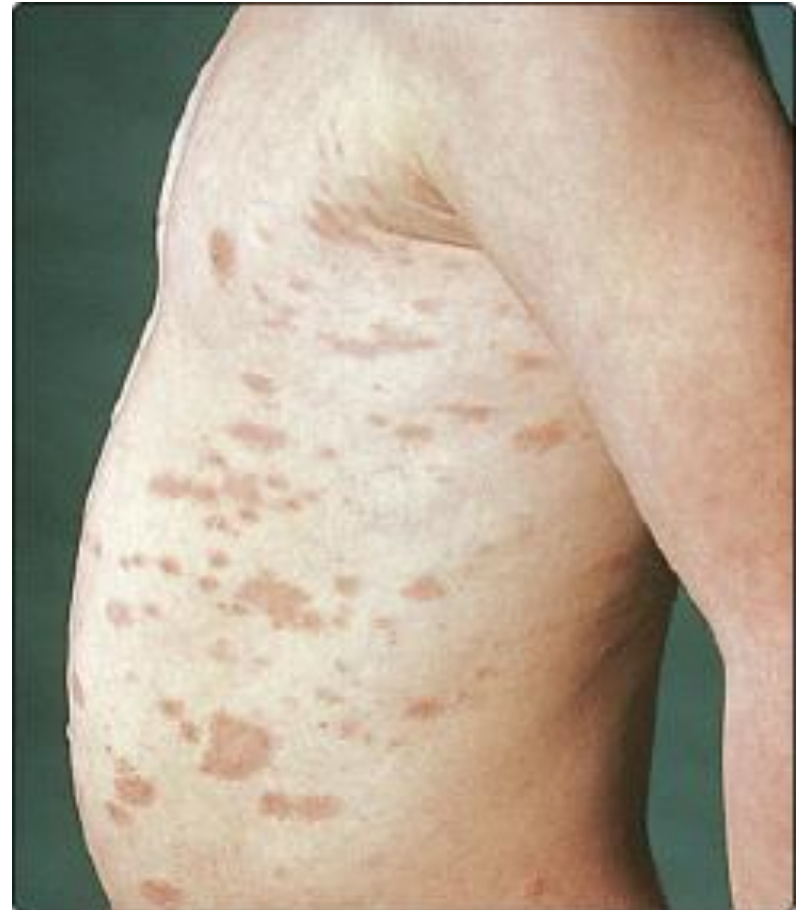

Cellulitis Ferri's Clinical Advisor 2018. Published January 1, 2018. Pages 265-266.e2. © 2018. FIG. E1 From White GM, Cox NH, eds: Diseases of the skin, ed 2, St Louis, 2006, Mosby. Erysipelas of the leg.B My Athens/ Clinical Key



Pityriasis Rosea

- Signs and Symptoms
 - Numerous flesh-colored or mildly erythematous papules and plaques with fine scaling
 - “Herald patch” and bilateral/symmetrical lesions
 - Patient does not look ill

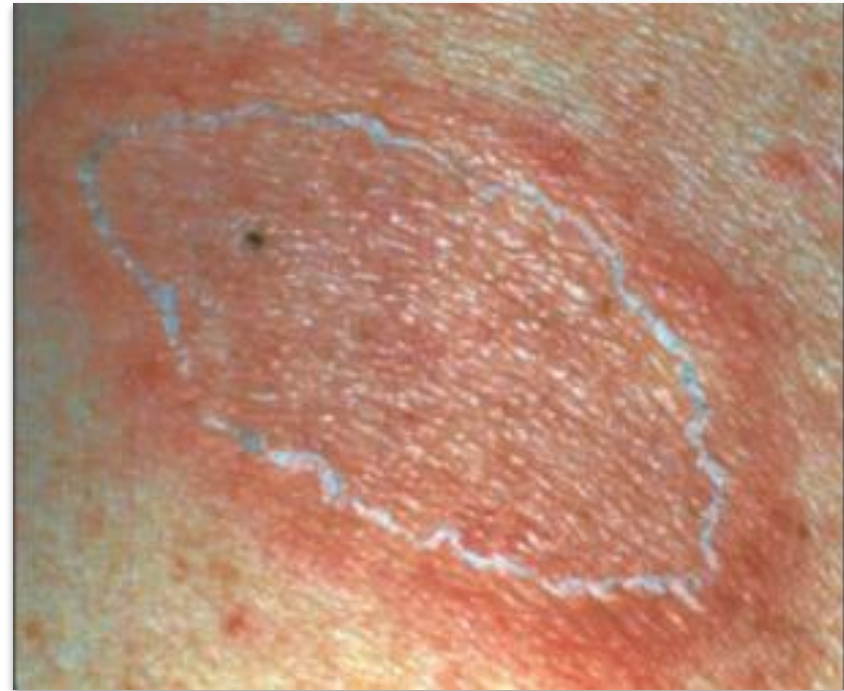

Papulosquamous eruptions Dermatology: An Illustrated Colour Text. Gawkrödger, Published January 1, 2017. Pages 44-45.e1. © 2017. Fig. 22.1. My Athens/ Clinical Key



Pityriasis Rosea Plan

- Symptomatic treatment
- No medications can cure
- Expose affected areas to the sun
- Lesions sometime take as long as 8 weeks to cure
- If persistent

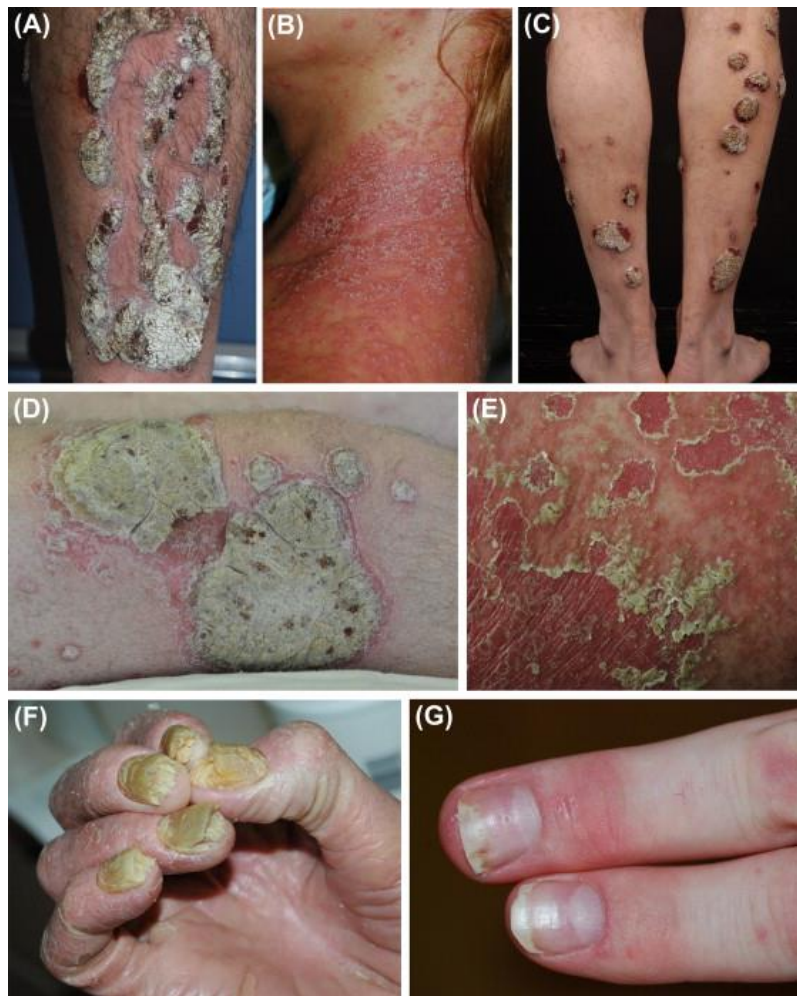

Pityriasis Rosea: Diagnosis and Treatment, American Family Physician. Published January 1, 2018. Volume 97, Issue 1. Pages 38-44. © 2018. Figure 2 Reprinted with permission from Stulberg DL, Wolfrey J. Pityriasis rosea. Am Fam Physician. 2004;69(1):88. My Athens/ Clinical Key



Psoriasis

- Chronic Disease
- Over production of new skin
- Areas of body
- Cosmetics issue

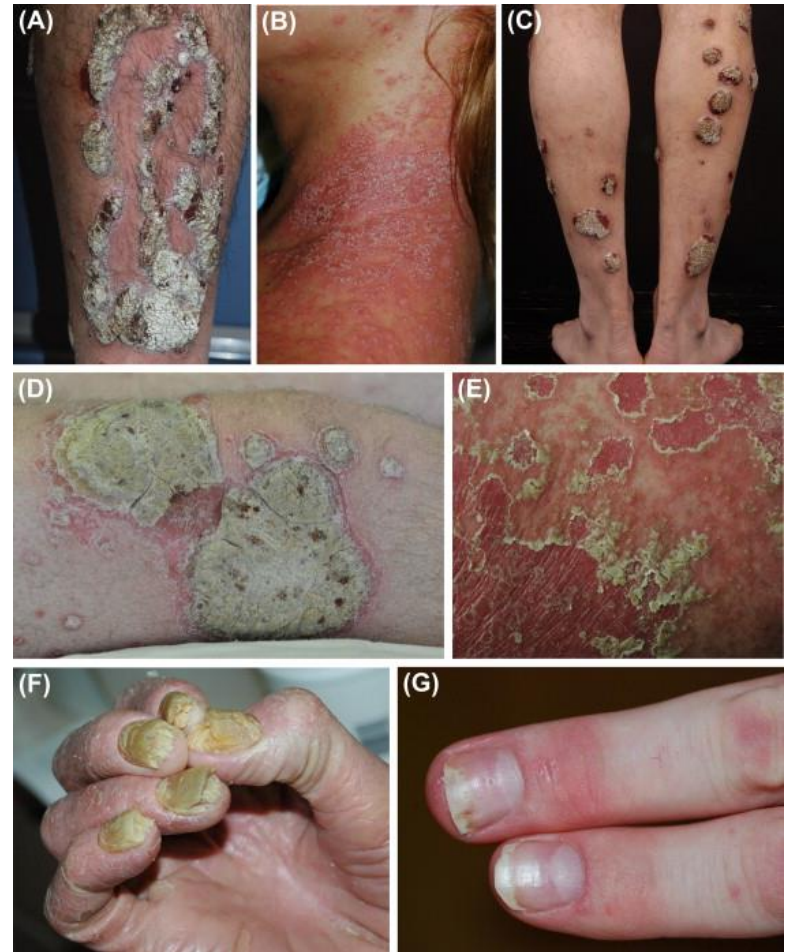

Psoriasis Emery and Rimoin's Principles and Practice of Medical Genetics. Published January 1, 2013. Pages 1-22. © 2013. FIGURE 150-2. My Athens/ Clinical Key



Psoriasis (Cont.)

- Signs and Symptoms
 - Irregularly shaped thickened plaques with flaky silver scales
 - Excoriation
 - Pitting of the nails
 - Arthritis

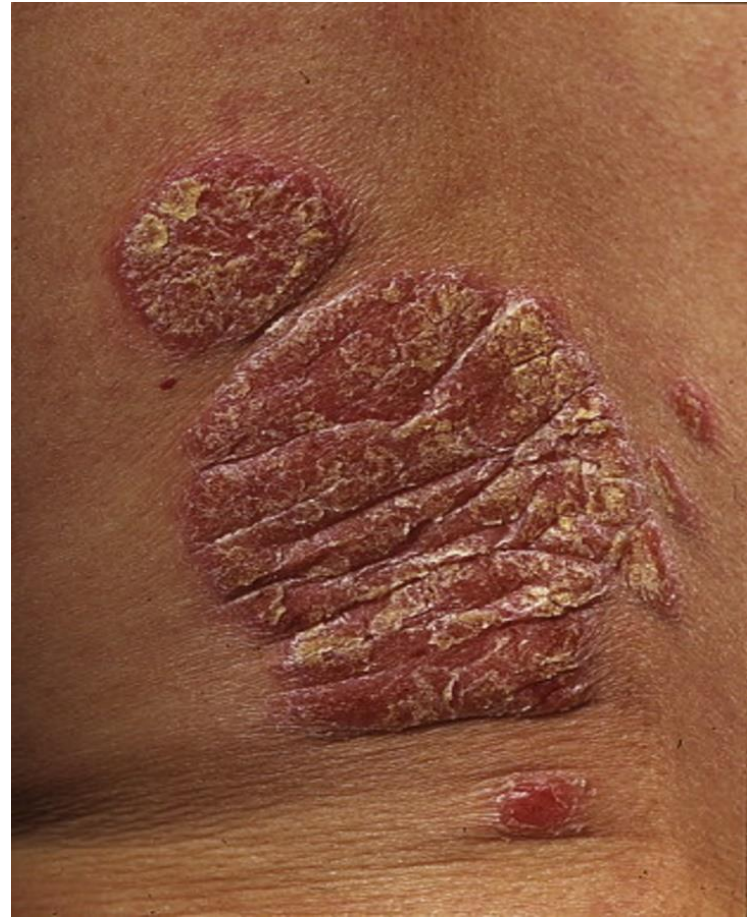

Psoriasis Emery and Rimoin's Principles and Practice of Medical Genetics. Published January 1, 2013. Pages 1-22. © 2013. FIGURE 150-2. My Athens/ Clinical Key



Psoriasis Plan

- Mild – Steroid cream & sun bathing
- Moderate – Topical steroid
- Severe – Dermatologic consultation



Psoriasis Clinical Overview. Published July 19, 2017. © 2017. Chronic plaque psoriasis, Psoriasis. Medicine. 37(5):235-41, Figure 1, 2009. My Athens/ Clinical Key

R³

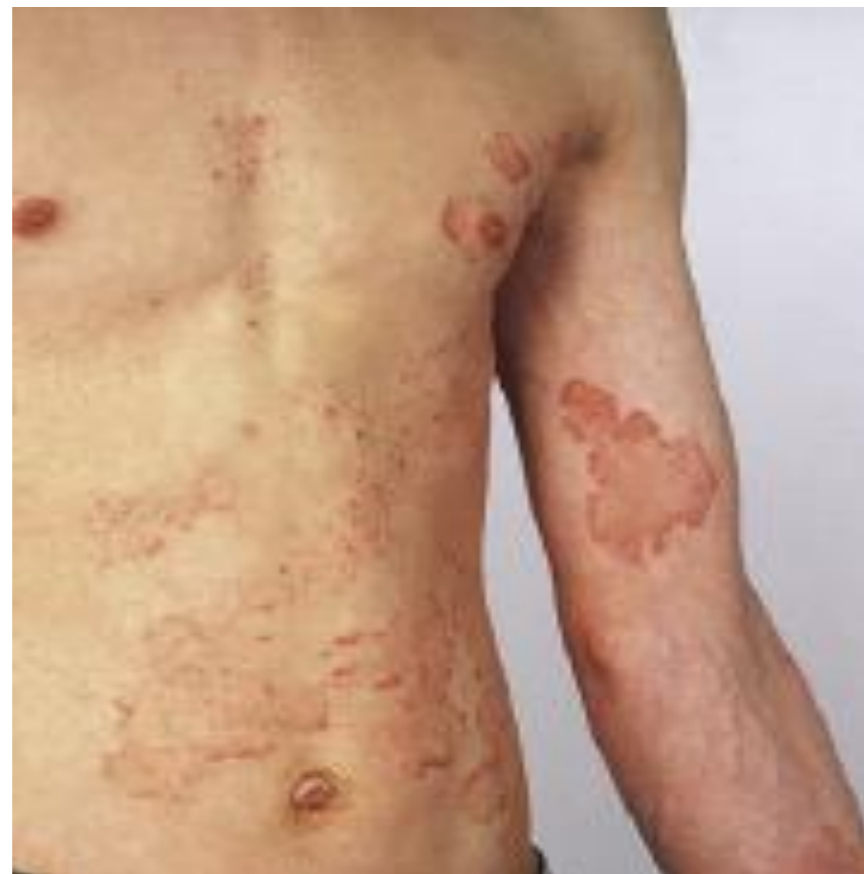2.10.2-54

Relevant, Responsive, Requested



Tinea Infections

- Signs and Symptoms
 - Findings range from mild scaling and erythema to exfoliation, fissuring and maceration.
 - It is prudent to take samples of the scales

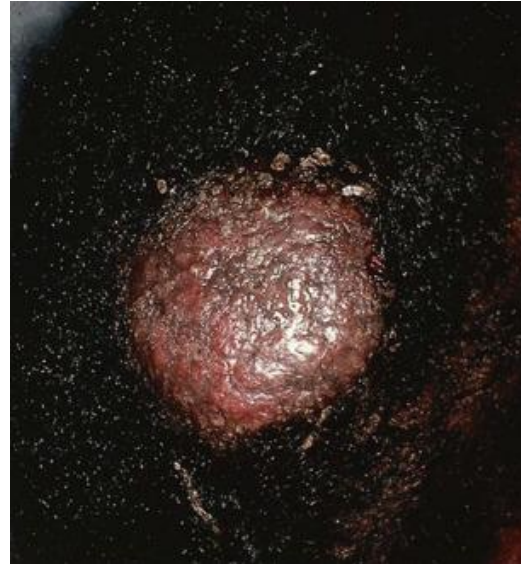


Tinea Pedis, Tinea Cruris, Tinea Corporis: (Athlete's Foot, Jock Itch, Ringworm) Minor Emergencies. Published January 1, 2012. Pages 733-739. © 2012. Figure 181-3 (From White G, Cox N: Diseases of the skin, ed 2. St Louis, 2006, Mosby.) Tinea corporis. My Athens/ Clinical Key

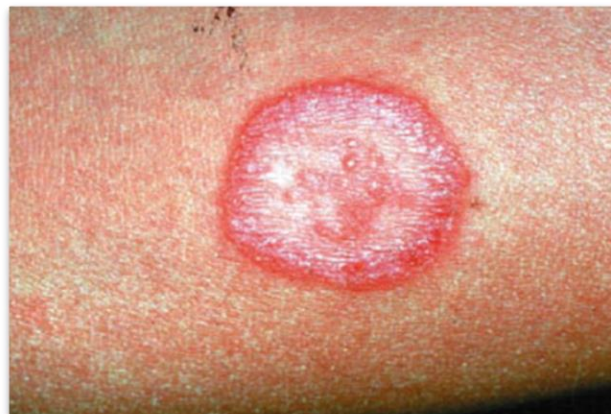

Tinea Capitis & Tinea Corporis

- Signs and Symptoms
 - Tinea Capitis
 - Areas of alopecia, scaling
 - Tinea Corporis
 - Annular lesions



Evaluation and Management of the Hair Loss Patient in the Primary Care Setting Primary Care: Clinics in Office Practice. Published December 1, 2015. Volume 42, Issue 4. Pages 569-589. © 2015. Fig. 11. MY Athens/ Clinical Key

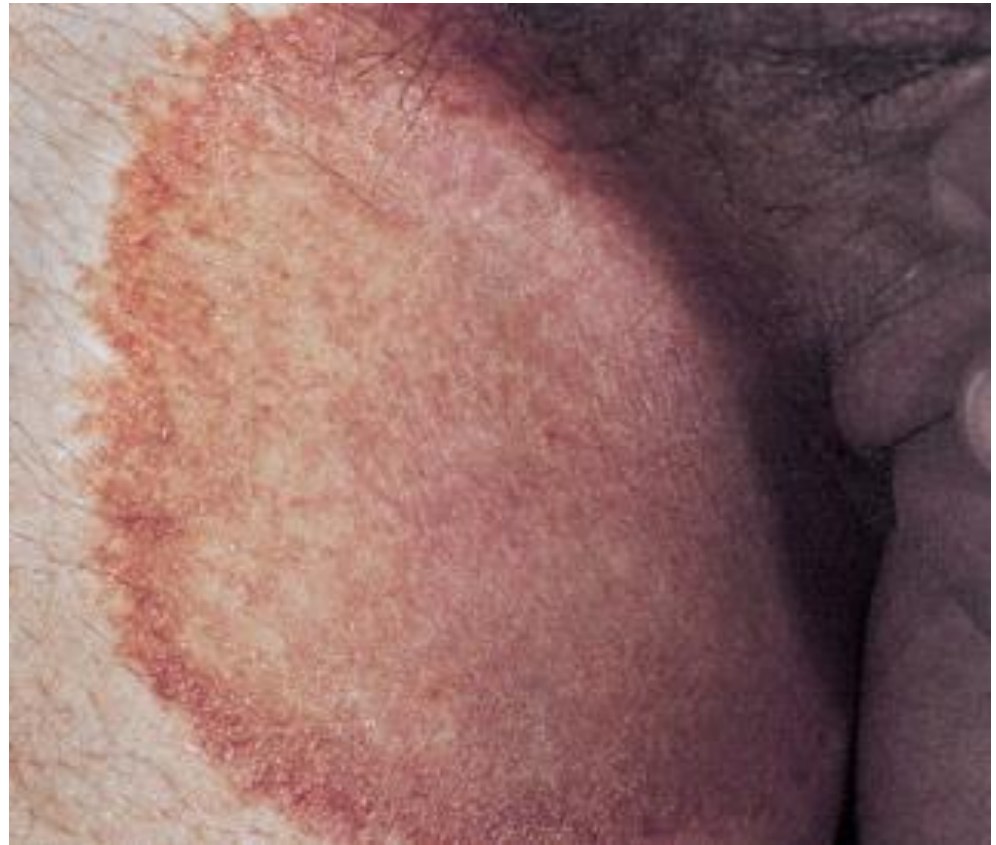

Dermatophyte infections Ferri's Color Atlas and Text of Clinical Medicine. Published January 1, 2009. Pages 110-114. © 2009. Fig 26-1 (Courtesy of Dr. M. M. Black, Institute of Dermatology, London.) Tinea corporis. MY Athens/ Clinical Key



Tinea Cruris

- Signs and Symptoms
 - Tinea Cruris
 - Intertriginous areas on adjacent upper thigh and buttock
 - Scrotum rarely ever involved

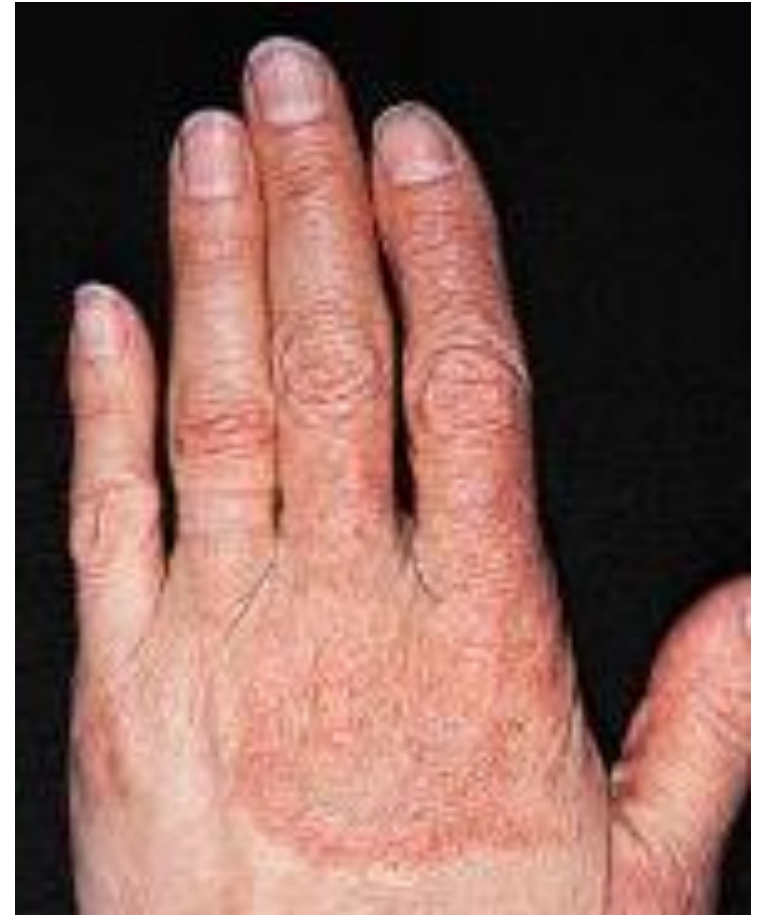

Topical therapy and topical corticosteroids Clinical Dermatology. Published January 1, 2016. Pages 75-89. © 2016. FIGURE 2-21. My Athens/ Clinical Key



Tinea Manus

- Signs and Symptoms
 - Tinea Manus
 - Usually in the dominant hand of a patient



Fungal Infections Skin Disease: Diagnosis and Treatment. Published January 1, 2018. Pages 241-281. © 2018. Fig. 9.85. My Athens/ Clinical Key

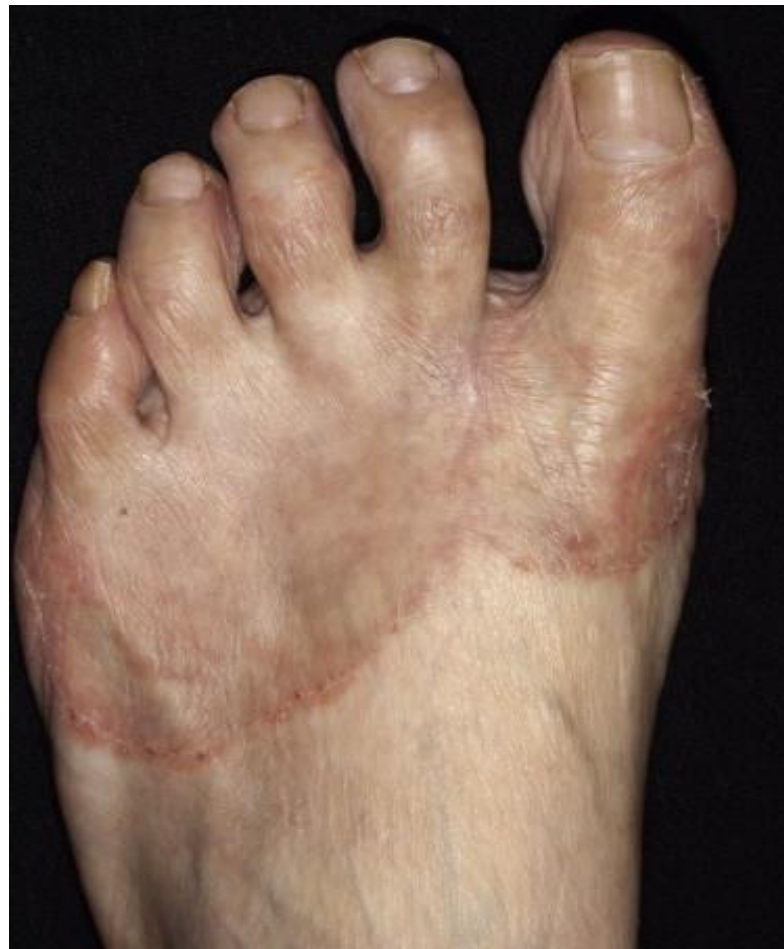

Tinea Pedis

- Signs and Symptoms

- Tinea Pedis

- Intensely pruritic
- May look like annular lesions with an advancing serpinginous borders with central clearing

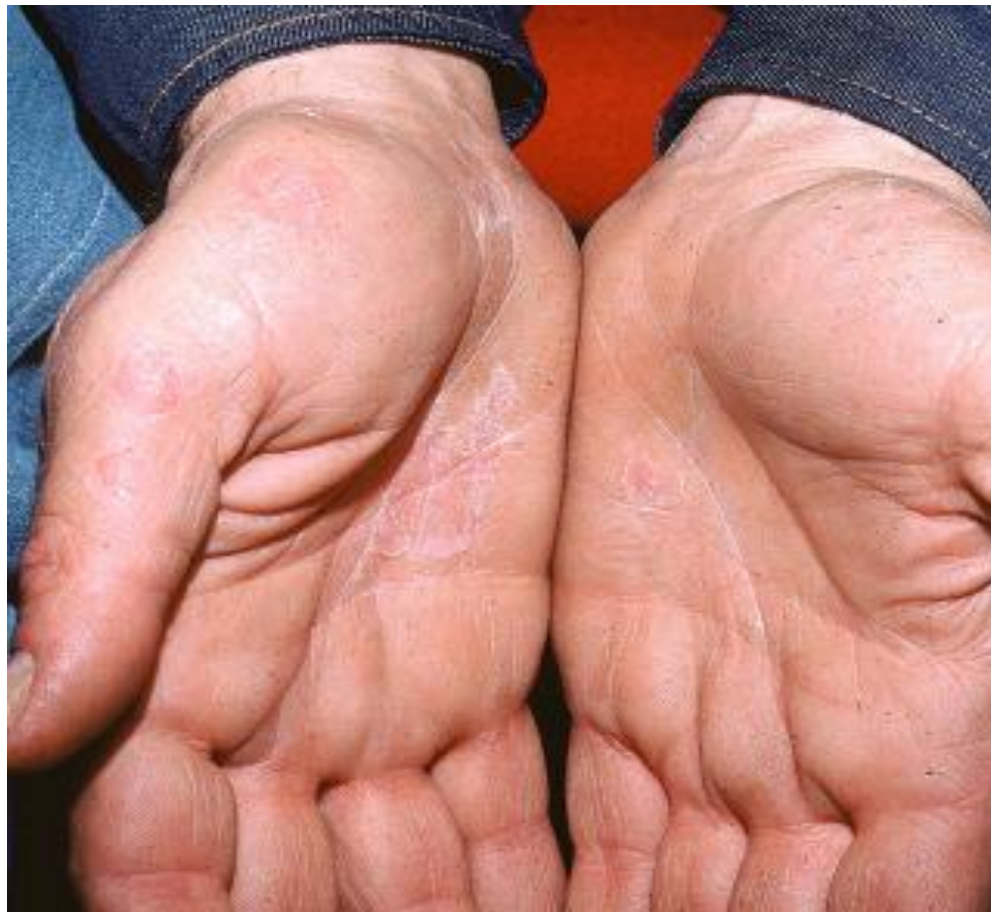

Superficial fungal infections Clinical Dermatology. Published January 1, 2016. Pages 487-533. © 2016. FIGURE 13-6 Tinea pedis. My Athens/ Clinical Key



Tinea Plan

- Topical antifungals
- Oral antifungals
- Foot powder
- Hygiene practices

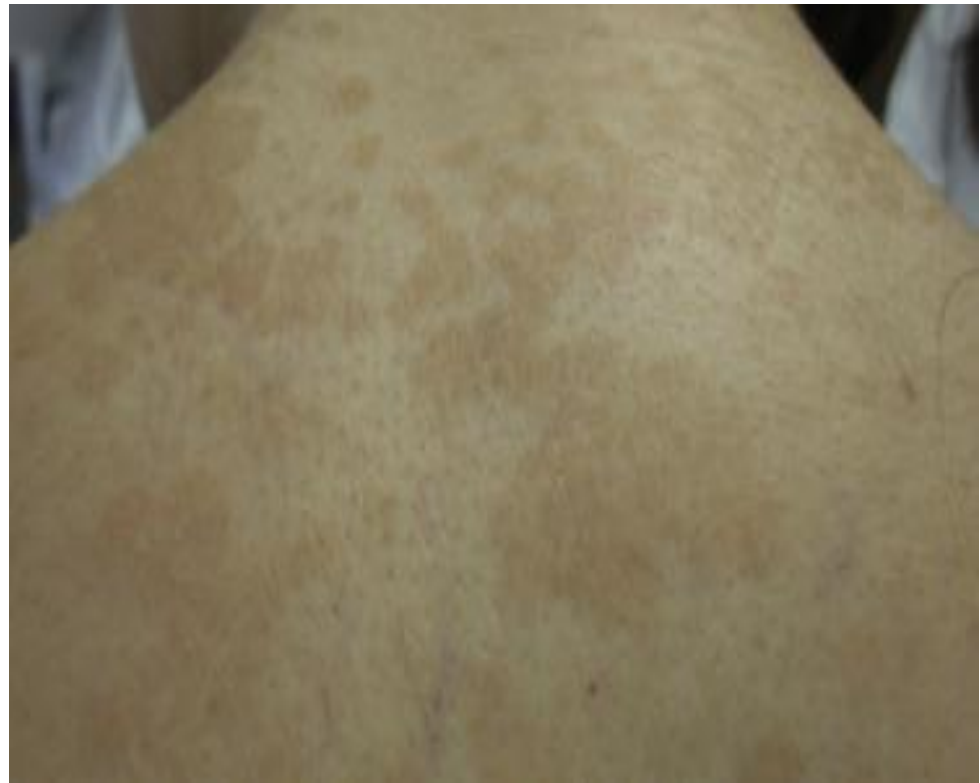

Dermatitis (Eczematoid Reactions) Urgent Care Dermatology: Symptom-Based Diagnosis. Published January 1, 2018. Pages 135-162. © 2018. Fig. 10.31. My Athens/ Clinical Key



Tinea Versicolor

- Signs and Symptoms
 - Fungal infection
 - Primarily on the back and chest
 - Hot, humid weather
 - Patches can be either lighter or darker than the surrounding skin

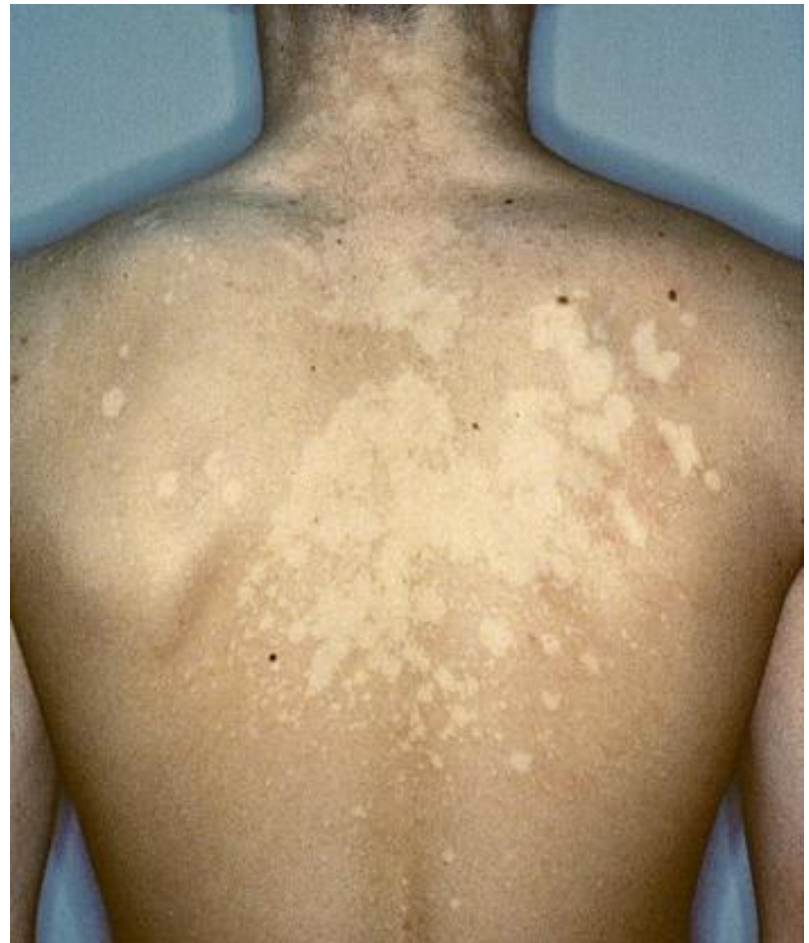

Tinea versicolor (pityriasis versicolor) Treatment of Skin Disease: Comprehensive Therapeutic Strategies. Published January 1, 2018. Pages 827-829. © 2018. My Athens/ Clinical Key



Tinea Versicolor Plan

- Selsun shampoo
- Educate patient
- If no resolution

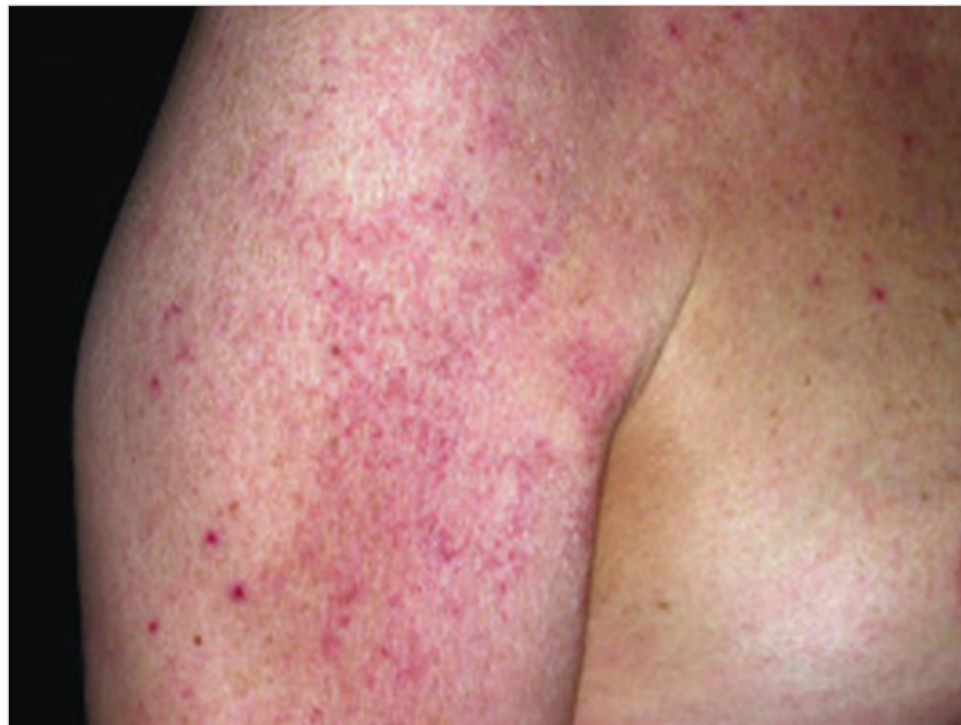

The Skin Textbook of Physical Diagnosis. Published January 1, 2014. Pages 81-144.e1. © 2014. Figure 5-78. My Athens/ Clinical Key



Eczema

- Signs and Symptoms
 - Eczematous inflammation
 - Redness, scaling, vesicles and itching

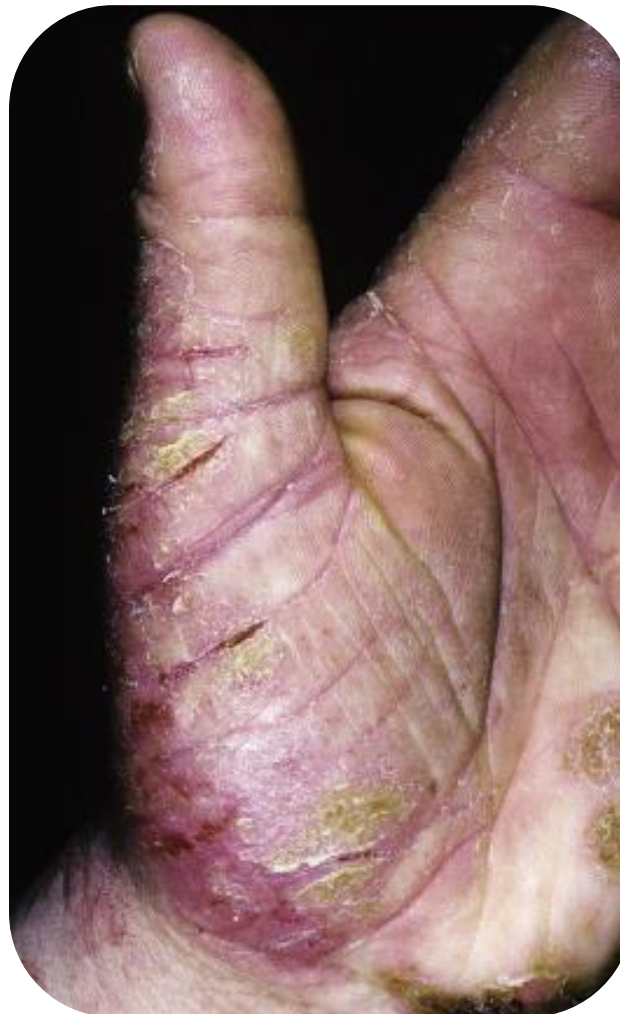

Eczema Skin Disease: Diagnosis and Treatment. Published January 1, 2018. Pages 12-84. © 2018. Fig. 2.18. My Athens/ Clinical Key



Eczema Plan

- Topical and systemic corticosteroids
- Educate patients

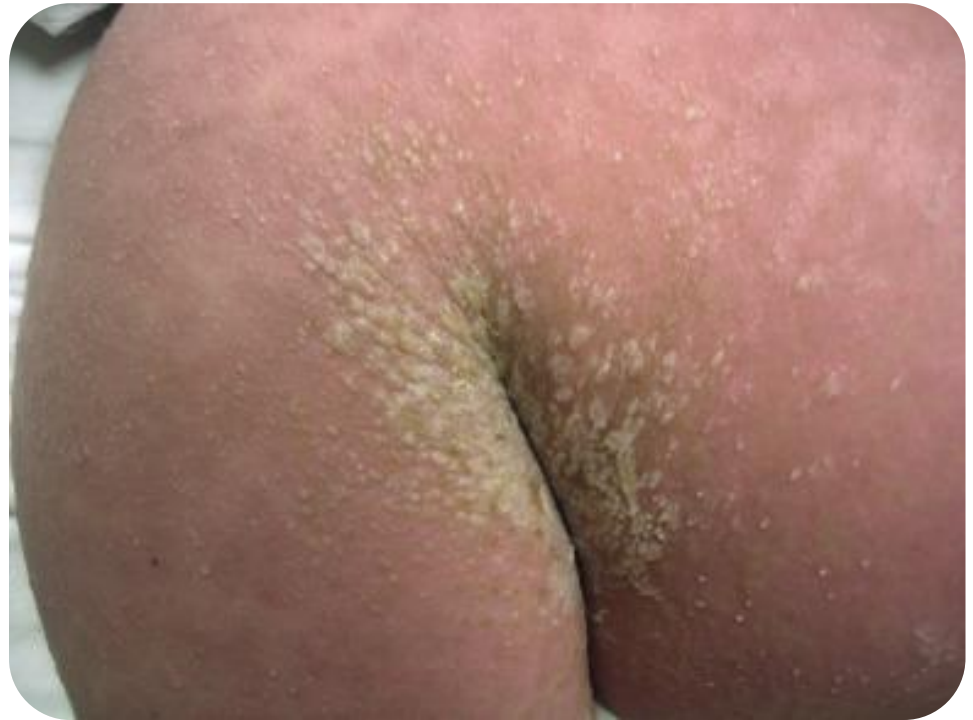

Eczema Skin Disease: Diagnosis and Treatment. Published January 1, 2018. Pages 12-84. © 2018. Fig. 2.32. My Athens/ Clinical Key



Contact Dermatitis

- Signs and Symptoms
 - Intensely pruritic and becomes erythematous
 - Grouped vesicles/bullae of varying sizes
 - Lesions erupt, weep and painful

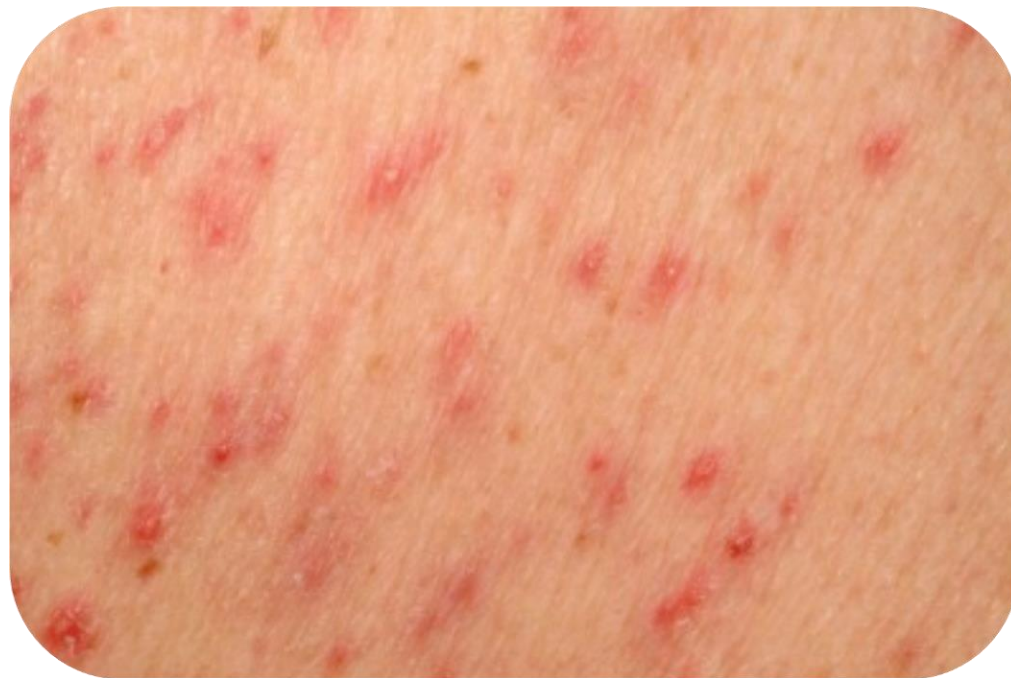

Contact Dermatitis and Drug Eruptions Andrews' Diseases of the Skin Clinical Atlas. Published January 1, 2018. Pages 65-85. © 2018. Fig. 6.59. My Athens/ Clinical Key



Contact Dermatitis Plan

- Antihistamines
- Wash the exposed area with soap and water
- Topical medications
- Instruct patient to avoid irritating agents

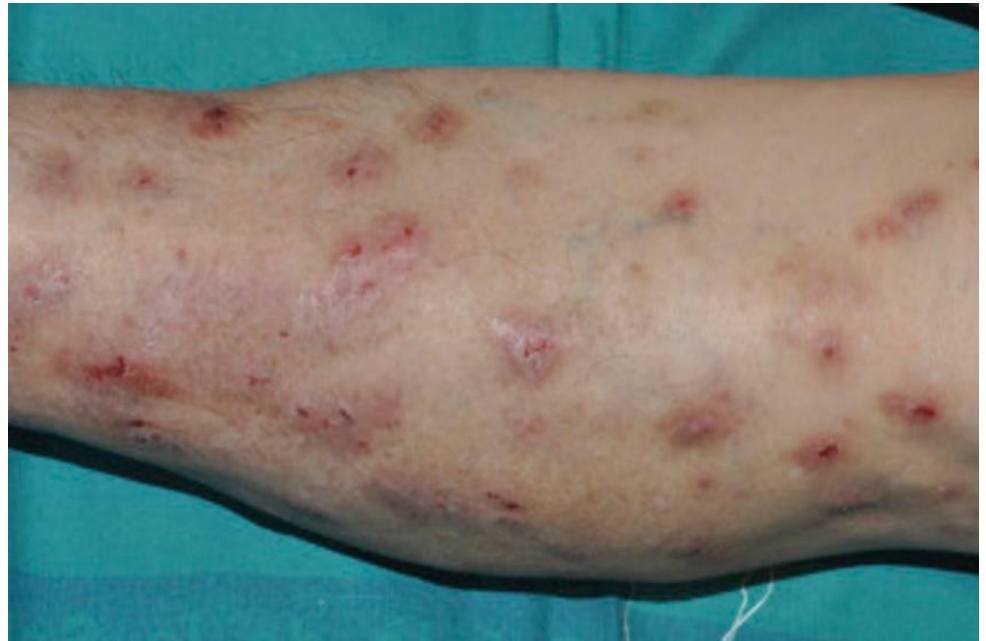

Contact Dermatitis and Drug Eruptions Andrews' Diseases of the Skin. Published January 1, 2016. Pages 90-135.e2. © 2016.



Atopic Dermatitis

- Signs and Symptoms
 - Erythematous scaling skin
 - Blisters, oozing and crusting
 - Markedly dry, thickened and scratched

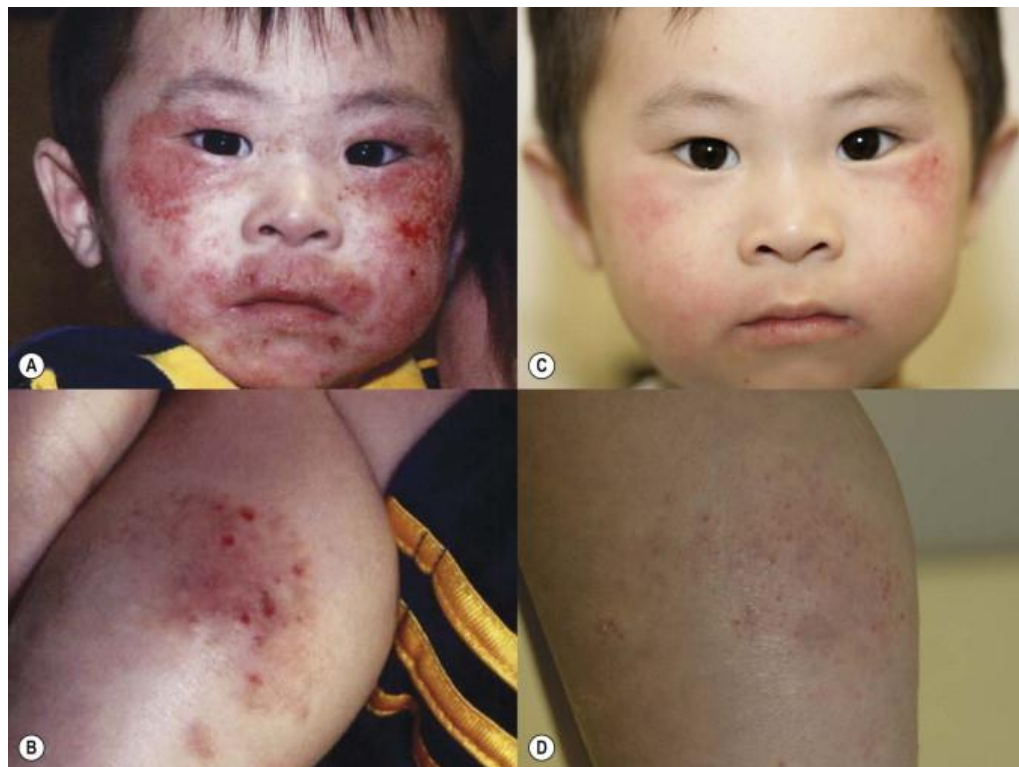

Atopic dermatitis/eczema Clinical Overview. Published December 14, 2017. © 2017. Piel. 31(1):15-23, 2016, Figure 5. My Athens/ Clinical Key



Atopic Dermatitis Plan

- Topical steroids
- Oral antihistamines
- Oral antibiotics
- Good skin care



Atopic Dermatitis and Food Allergy Food Allergy. Published January 1, 2012. Pages 61-73. © 2012. Figure 5.1. My Athens/ Clinical Key

R³

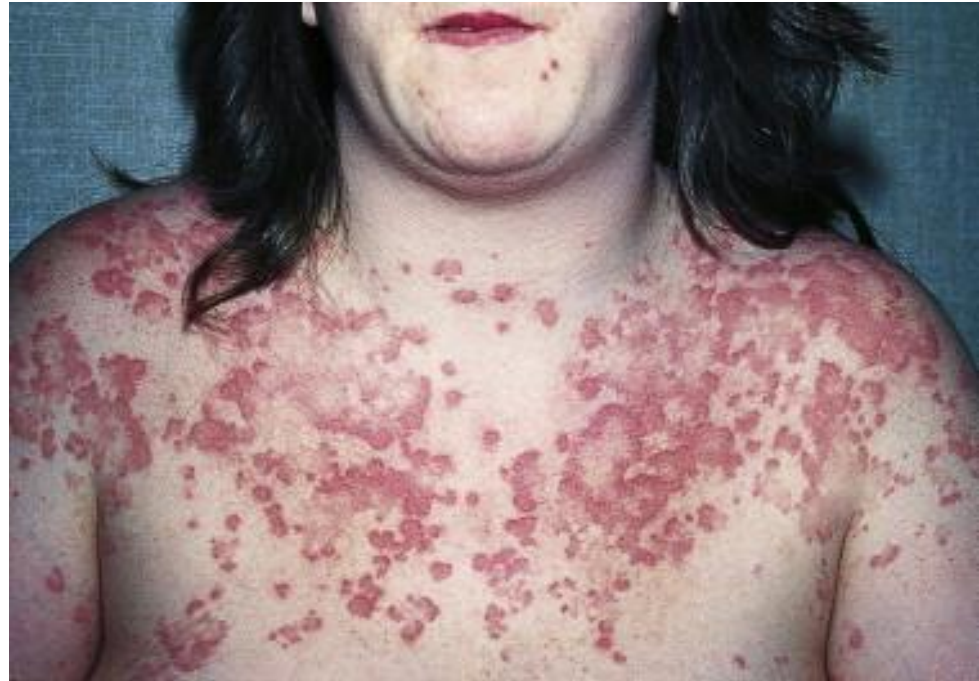Relevant, Responsive, Requested

2.10.2-68



Urticaria

- Signs and Symptoms
 - Generalized distribution of well circumscribed wheals with red, raised borders
 - May be the first sign of Anaphylaxis

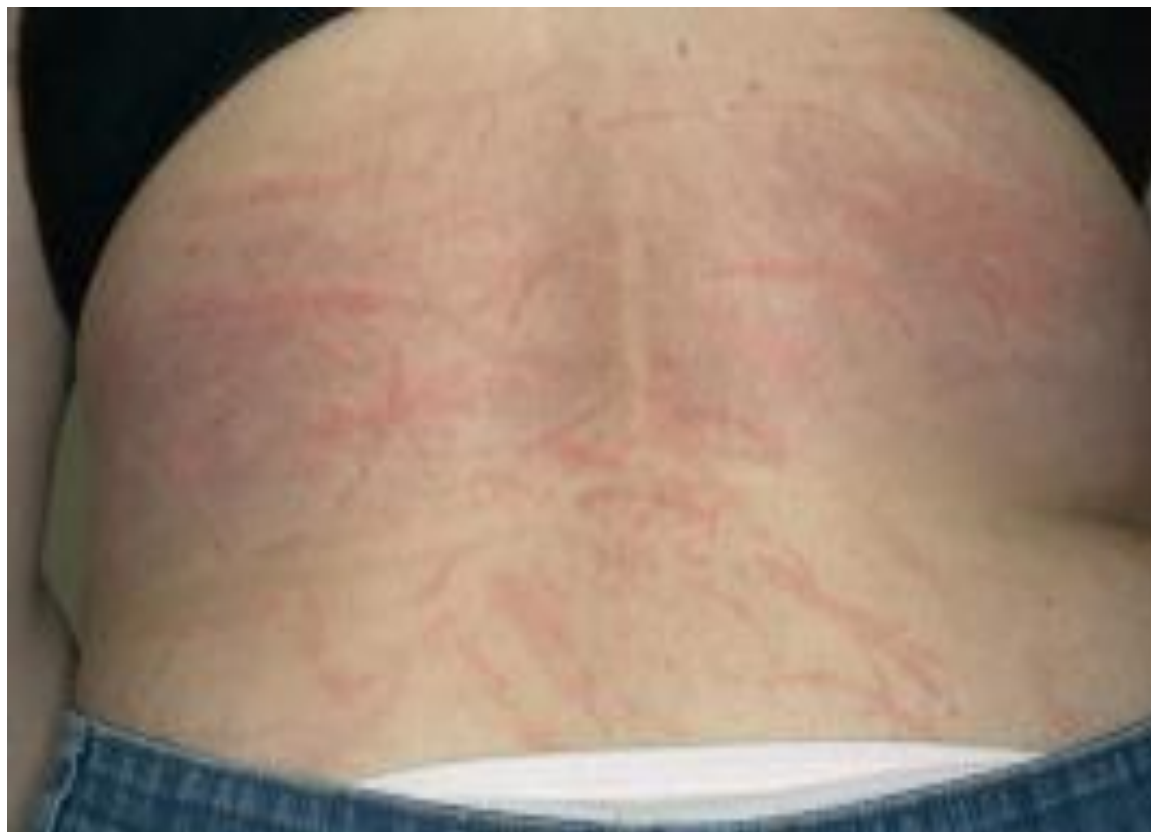

Urticaria, angioedema, and pruritus Clinical Dermatology. Published January 1, 2016. Pages 178-217. © 2016. FIGURE 6-11. My Athens/ Clinical Key



Urticaria Plan

- Antihistamines
- Call medical officer immediately if evidence of anaphylactic reaction

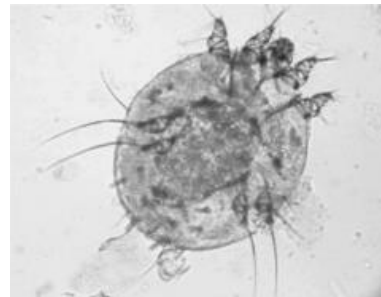


Urticaria Skin Disease: Diagnosis and Treatment. Published January 1, 2018. Pages 85-100. © 2018. Fig. 3.10. My Athens/ Clinical Key

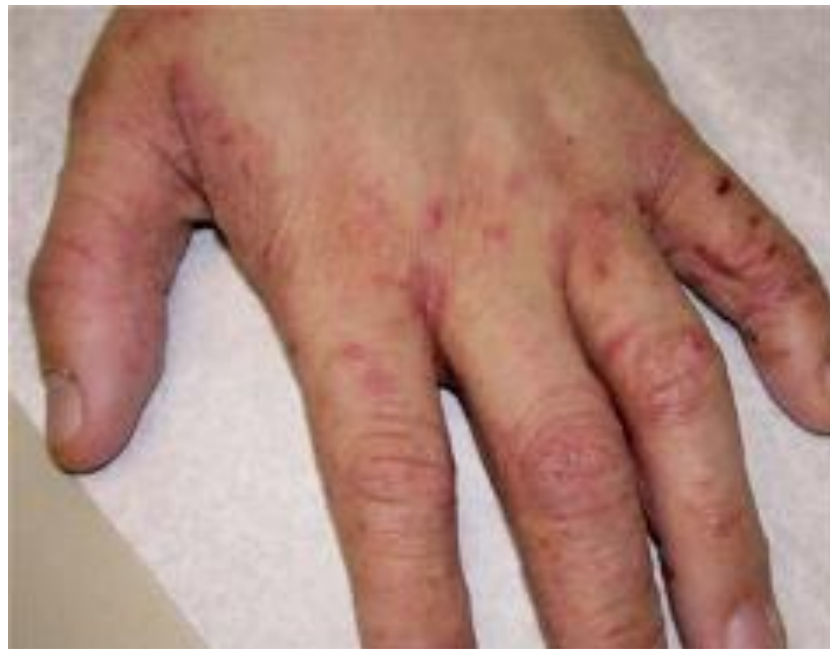

Scabies

- Signs and Symptoms
 - May not appear up to a month
 - Gray – brown or skin colored ridges
 - Secondary bacterial infections



Scabies Crustosa Following Corticosteroid Therapy in an Elderly Patient American Journal of the Medical Sciences, The. Sivasubramanian, Published March 1, 2012. Volume 343, Issue 3. Pages 248-248. © 2012. Figure 2. My Athens/ Clinical Key

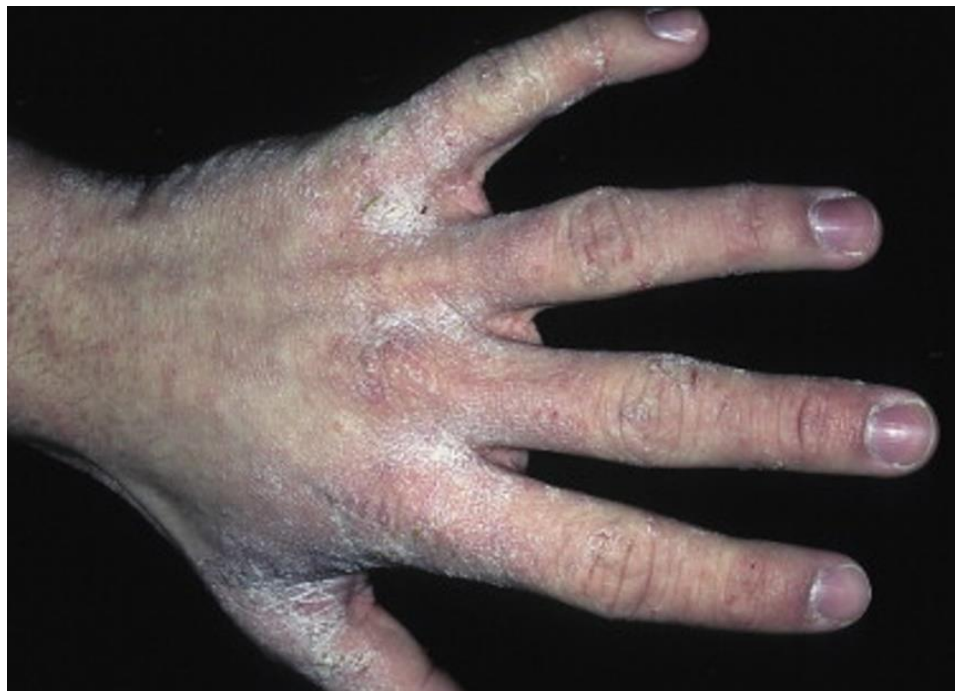

Scabies Clinical Overview. Published May 12, 2016. © 2017. My Athens/ Clinical Key



Scabies Plan

- Topical medication
- Close contacts should also be treated simultaneously
- Personal items should be washed
- Refer to provider for isolation procedures



Scabies Clinical Overview. Published May 12, 2016. © 2017. My Athens/ Clinical Key



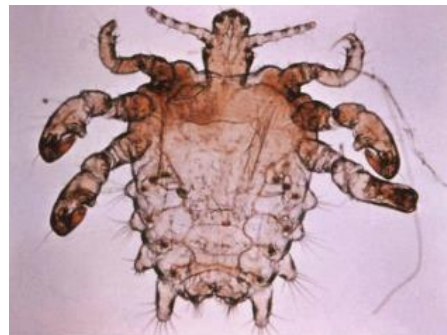Pediculosis

- Signs and Symptoms

- Itching in the involved areas
- Lice and eggs (nits) cemented to the bases of hair shafts close to the skin



Pediculosis
Clinical
Overview.
Published
September 10,
2015. © 2017.
My Athens/
Clinical Key



Lice (Pediculosis) Mandell, Douglas, and Bennett's
Principles and Practice of Infectious Diseases,
Updated Edition. Published January 1, 2015. Pages
3246-3249.e1. © 2015. FIGURE 294-3. My Athens/
Clinical Key



Pediculosis Plan

- Good hygiene measures
- Recommend shaving hair

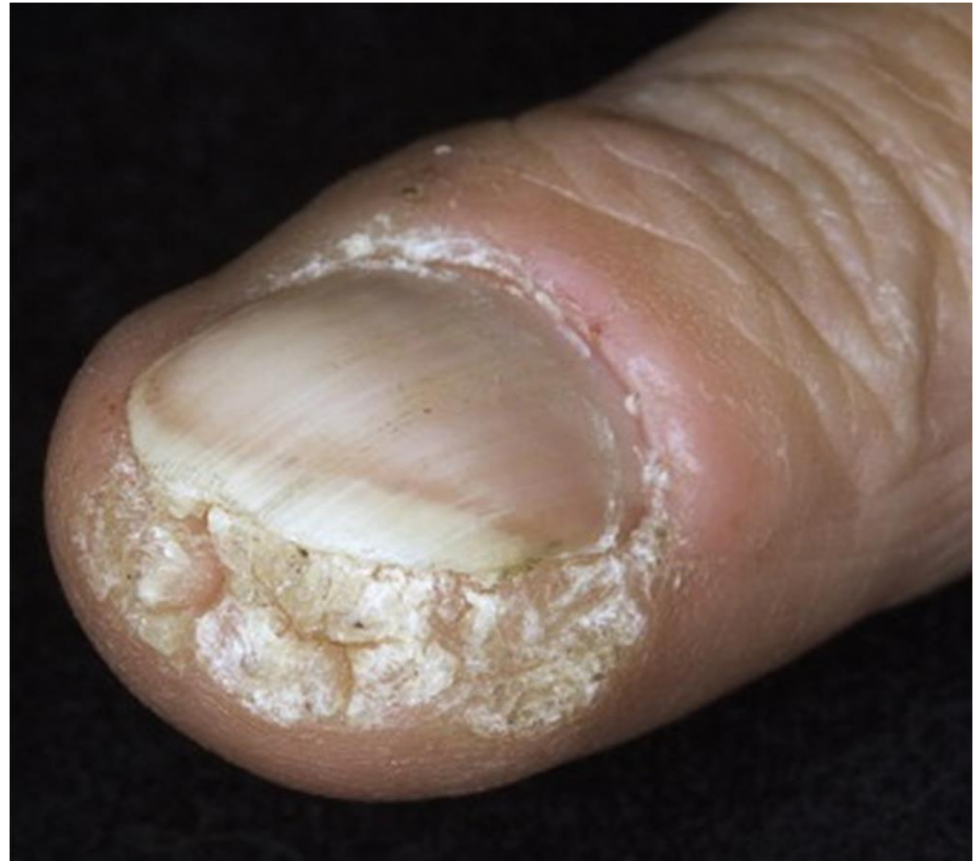

Lice (Pediculosis) Mandell, Douglas, and Bennett's Principles and Practice of Infectious Diseases, Updated Edition. Published January 1, 2015. Pages 3246-3249.e1. © 2015. FIGURE 294-2. My Athens/ Clinical Key



Warts

- Signs and Symptoms
 - Flesh colored
 - Dome shaped
 - Firm papule
 - Corrugated surface

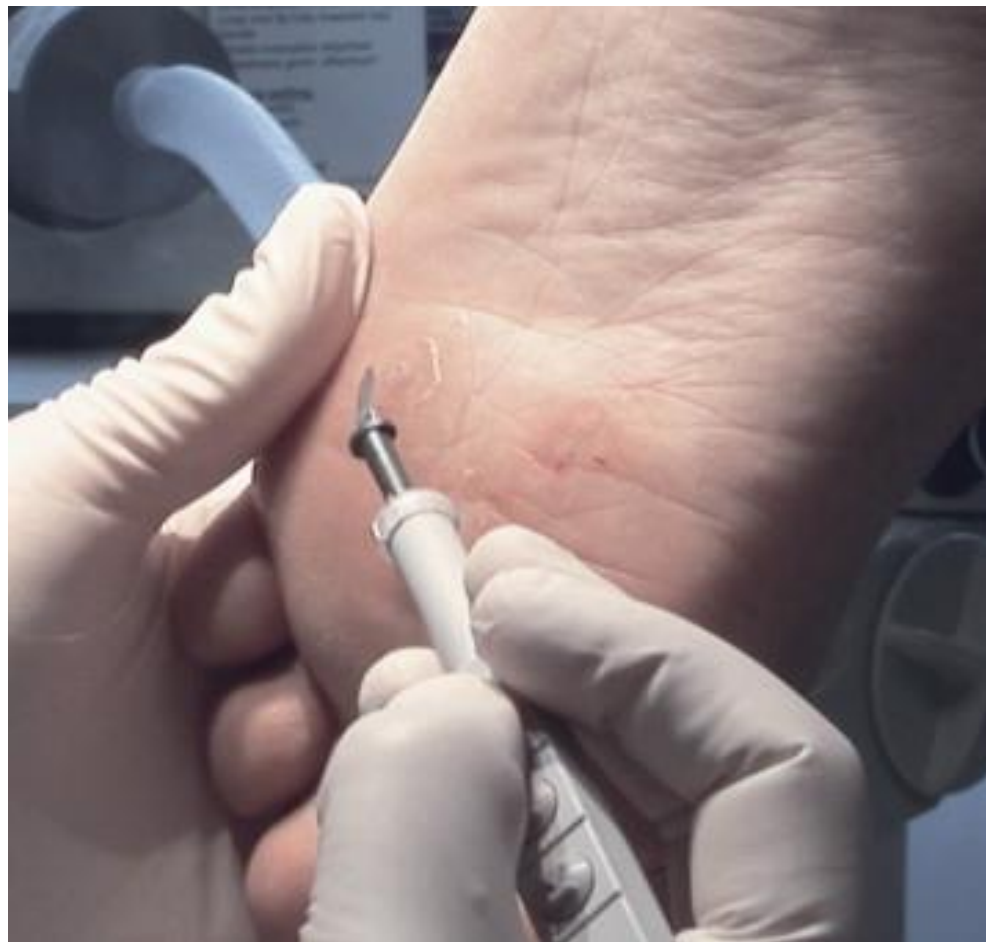

Warts, herpes simplex, and other viral infections Clinical Dermatology. Published January 1, 2016. Pages 448-486. © 2016. FIGURE 12-26. My Athens/Clinical Key



Warts Plan

- Cryotherapy with liquid nitrogen
- Only a medical provider should use cryotherapy on genital warts

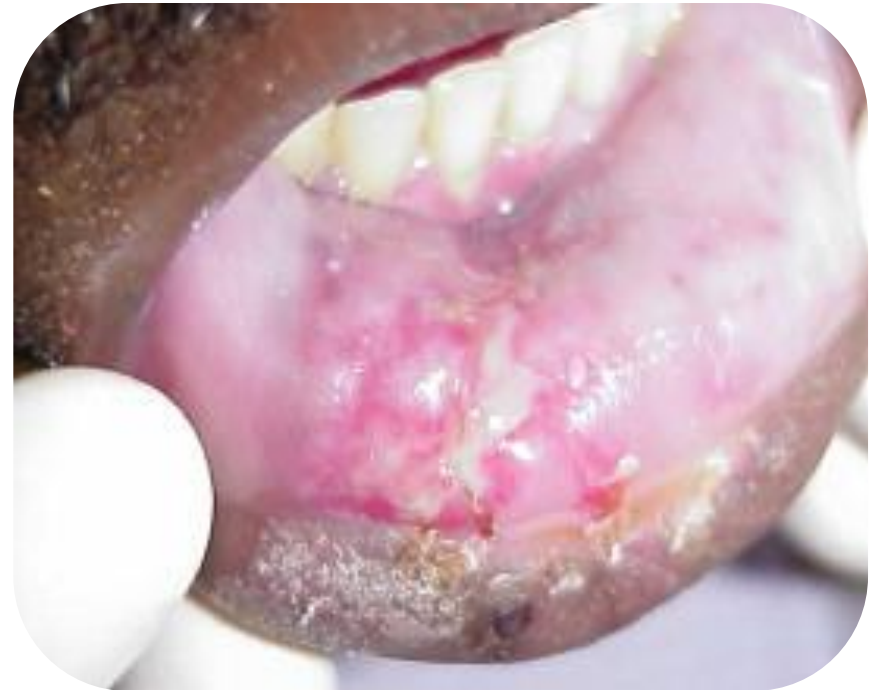

Wart Treatment Atlas of Essential Procedures. Published January 1, 2011. Pages 26-29. © 2011. FIGURE 7-4. My Athens/ Clinical Key



Herpes

- Signs and Symptoms
 - Clustered vesicles
 - Painful ulcerated lesions
 - Erythematous base
 - Develop on pharyngeal and oral mucosa
 - Rapidly ulcerate, and increase in number

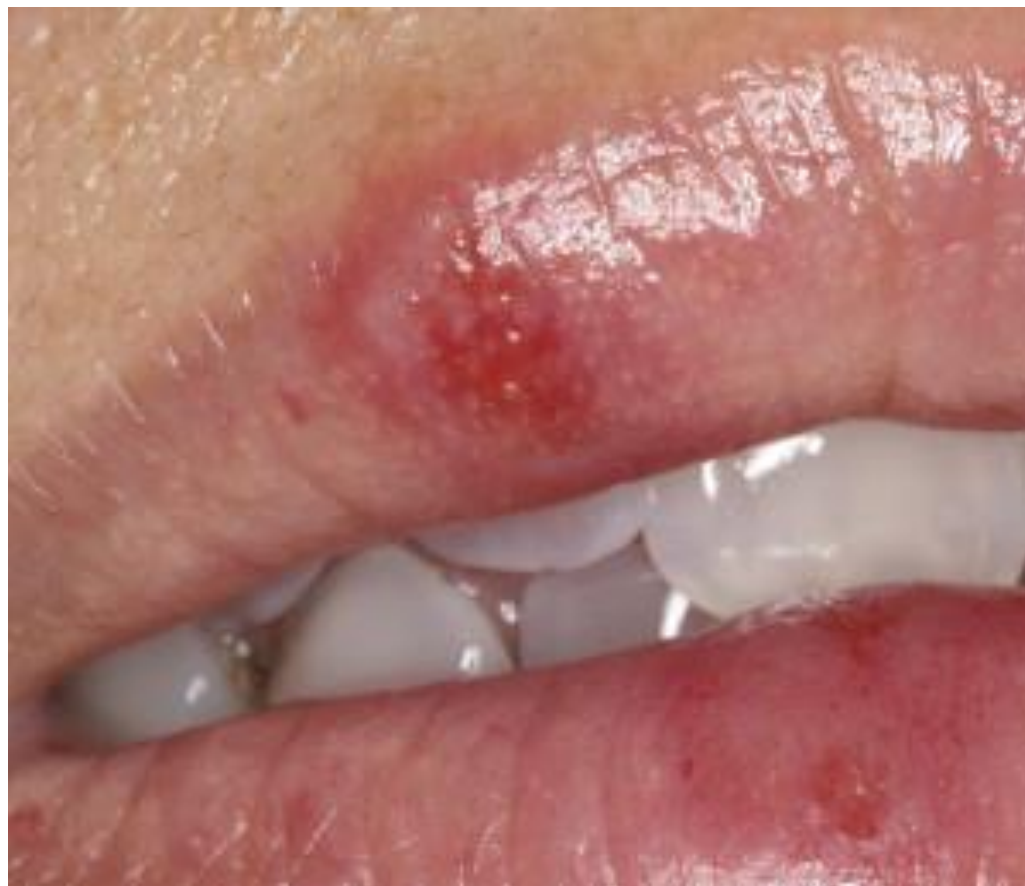

Human herpes simplex virus infections: Epidemiology, pathogenesis, symptomatology, diagnosis, and management
Journal of the American Academy of Dermatology.
Published November 1, 2007. Volume 57, Issue 5. Pages 737-763. © 2007. Fig 7. My Athens/ Clinical Key



Herpes Plan

- Acyclovir
- Valacyclovir
- Avoid salty, acidic, or sharp foods
- Reinforce safe sexual practices

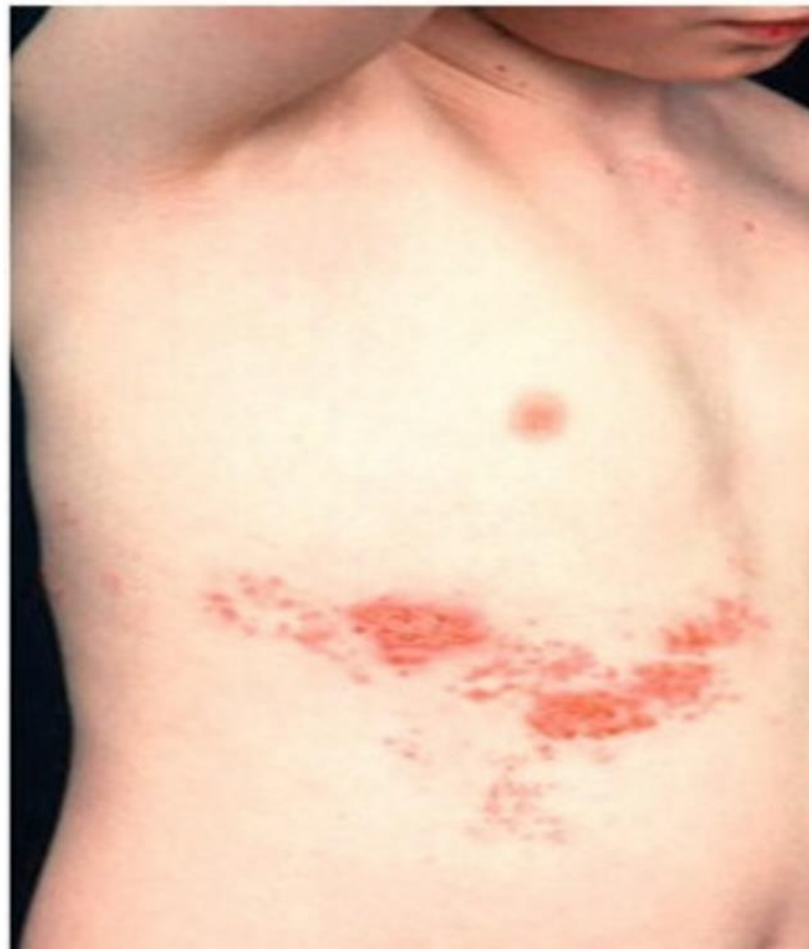

Update on Oral Herpes Virus Infections Dental Clinics of North America. Published April 1, 2014. Volume 58, Issue 2. Pages 265-280. © 2014. Fig. 2. My Athens/Clinical Key



Shingles (Herpes Zoster)

- Signs and Symptoms
 - Prodromal Phase
 - Tingling, paresthesias
 - Itching
 - Boring "knife-like" pain
 - Acute Phase
 - Rash
 - Vesicles

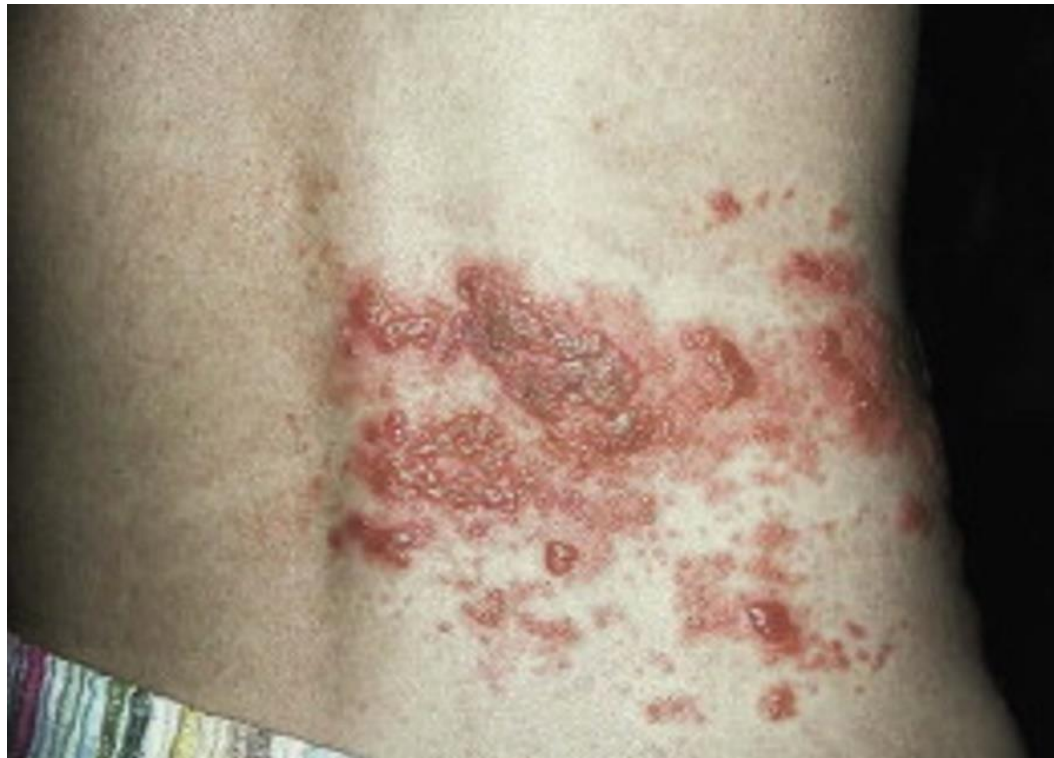

Herpes zoster infection (shingles) Clinical Overview.
Published December 15, 2015. © 2017. My Athens/ Clinical Key



Herpes Zoster Plan

- Antiviral agents
- Warn of potential risk of transmitting illness



Herpes zoster infection (shingles) Clinical Overview.
Published December 15, 2015. © 2017. My Athens/ Clinical Key

R³

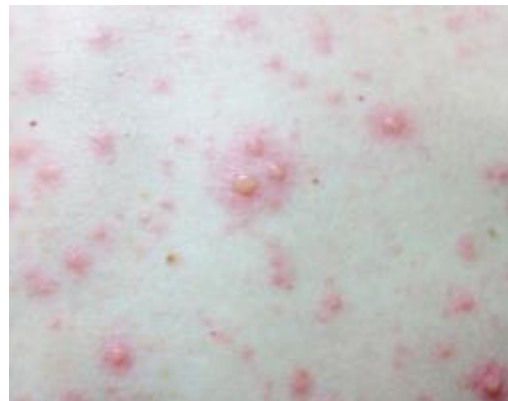Relevant, Responsive, Requested

2.10.2-80

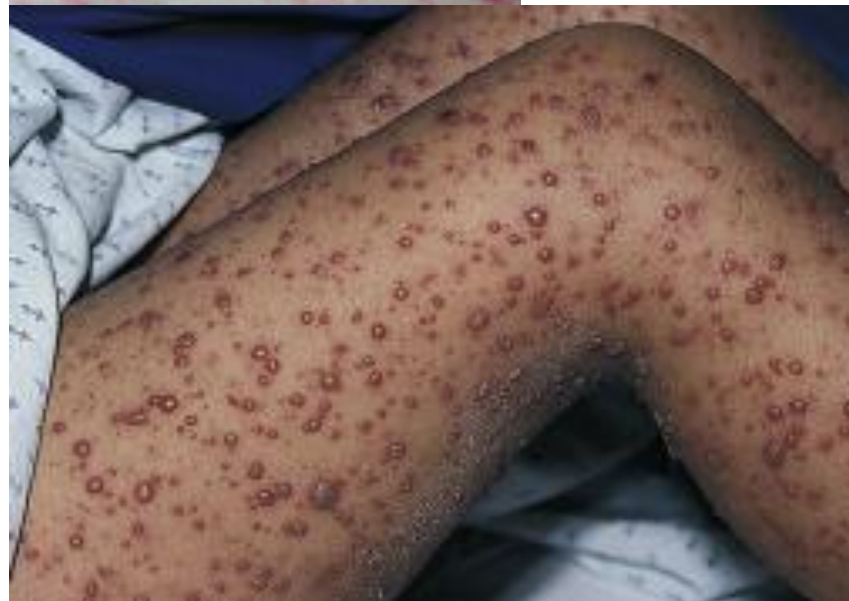

Chickenpox

- Signs and Symptoms
 - Rash
 - Pruritic rash present in various stages
 - Lesions may be present on mucous membranes



Varicella Treatment of Skin Disease: Comprehensive Therapeutic Strategies. Published January 1, 2018. Pages 844-847. © 2018. My Athens/ Clinical Key

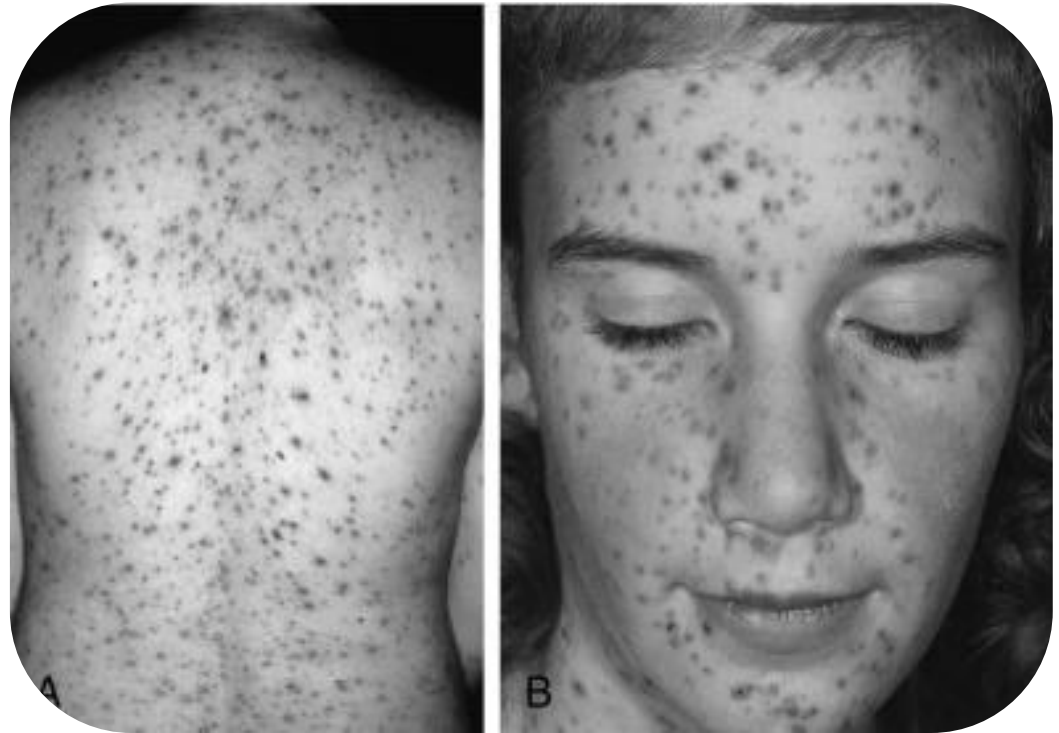


Varicella Ferri's Clinical Advisor 2018. Published January 1, 2018. Pages 1347-1347.e1. © 2018. FIG. 1. My Athens/ Clinical



Chickenpox Plan

- Supportive: antipyretics for fever
- Avoid aspirin in children
- Local and/or systemic antipruritic agents for itching

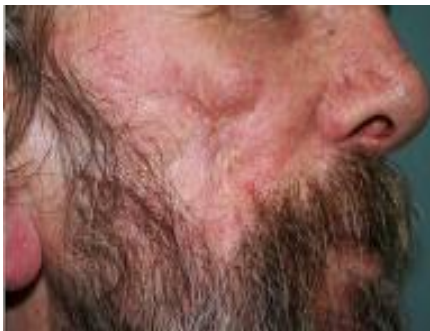
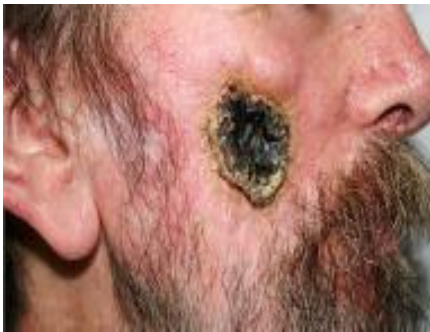
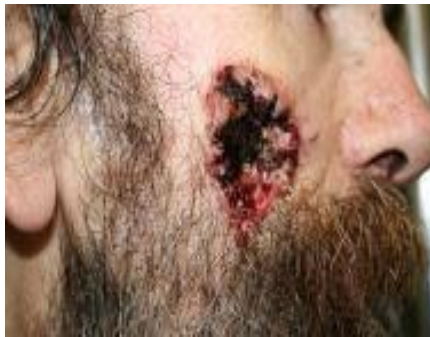Varicella (Chickenpox) Conn's Current Therapy 2018. Mayans, Laura, MD, MPH... Published January 1, 2018. Pages 642-644. © 2018. Figure 2. My Athens/Clinical Key



Skin Cancer

- Two distinct types:
 - Non-Melanoma Skin Cancer (NMSC)
 - Basal Cell Carcinoma (BCC)
 - Squamous Cell Carcinoma (SCC)
 - Melanoma

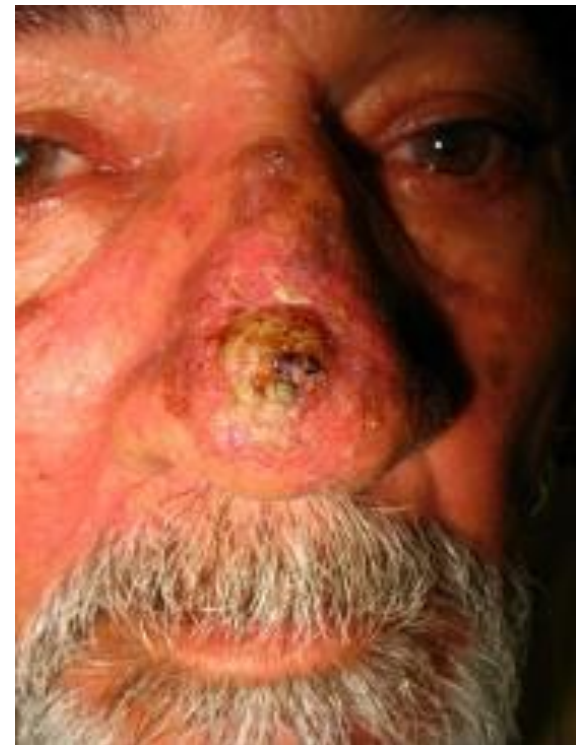
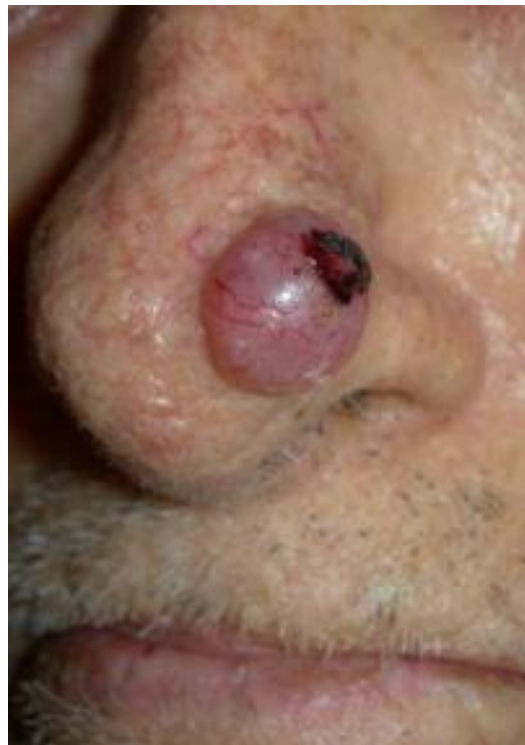
Results of the treatment of skin cancer European Journal of Cancer. Published August 1, 2016. Volume 63. Pages 41-52. © 2016. Fig. 4. My Athens/ Clinical Key



Basal Cell Carcinomas

- Slow growing malignant lesion that rarely metastasize

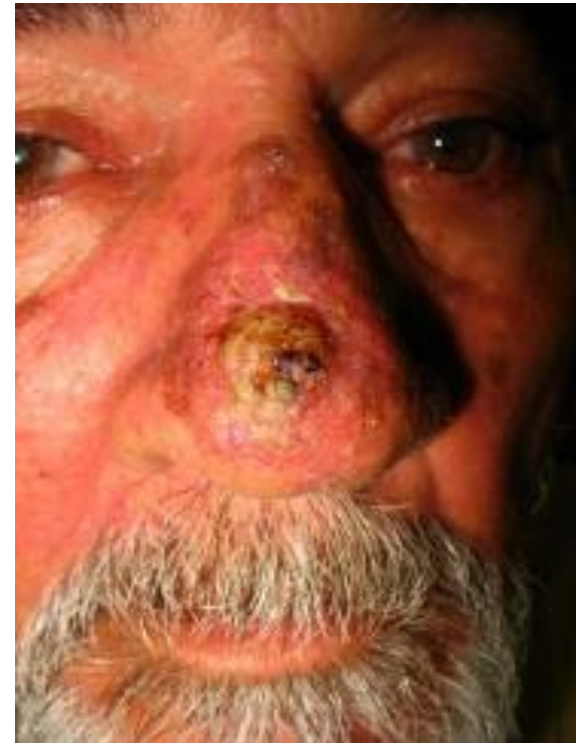
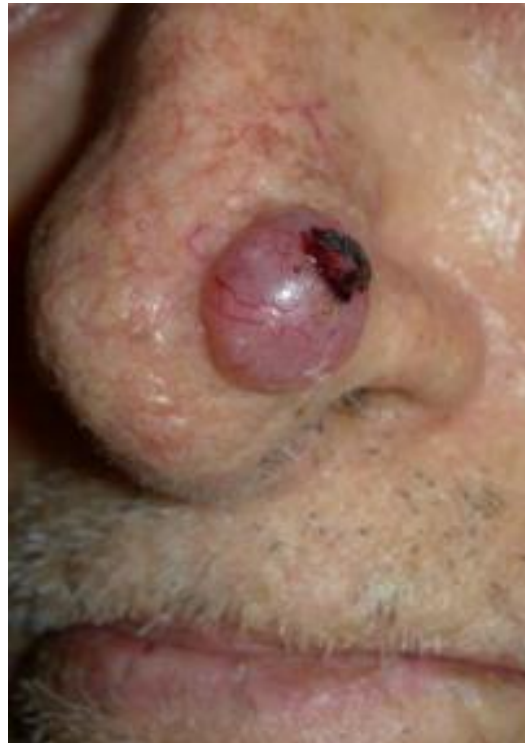
Both images from Malignant Skin Neoplasms Medical Clinics of North America. Published November 1, 2009. Volume 93, Issue 6. Pages 1241-1264. © 2009. Fig. 8. My Athens/ Clinical Key



Squamous Cell Carcinomas

- Extensive malignant lesion involving the dermis and epidermis

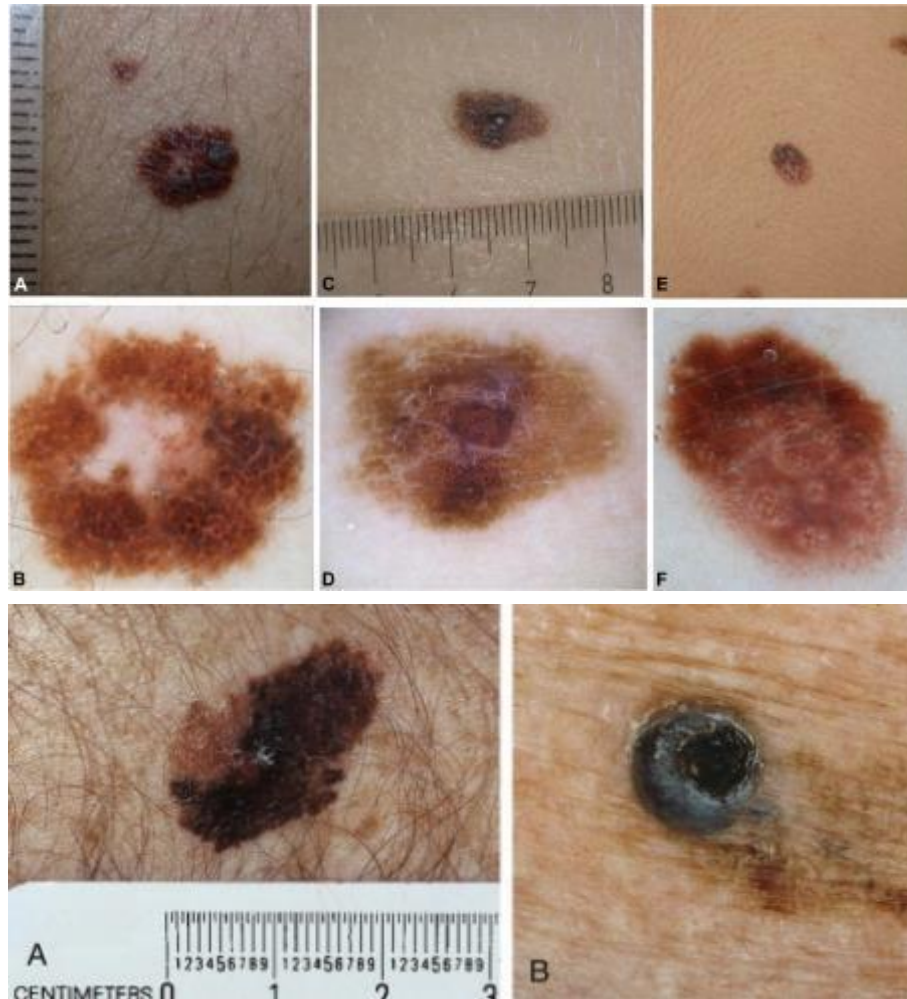


Both images from Malignant Skin Neoplasms Medical Clinics of North America. Published November 1, 2009. Volume 93, Issue 6. Pages 1241-1264. © 2009. Fig. 8. My Athens/ Clinical Key



Malignant Melanoma

- Deadliest
- ABCDE of Melanoma



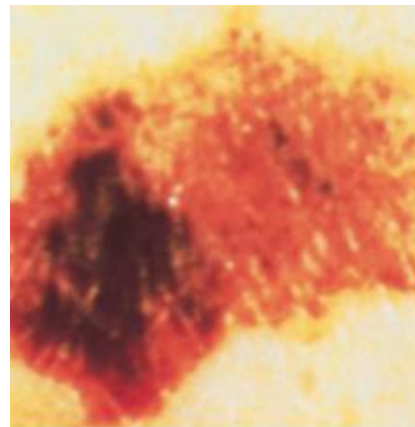
Clinical and dermoscopic characterization of pediatric and adolescent melanomas: Multicenter study of 52 cases *Journal of the American Academy of Dermatology* Published February 1, 2018. Volume 78, Issue 2. Pages 278-288. © 2017 My Athens/ Clinical Key.

Melanoma Dermatology Secrets Plus. Published January 1, 2016. Pages 398-412. © 2016. My Athens/ Clinical Key

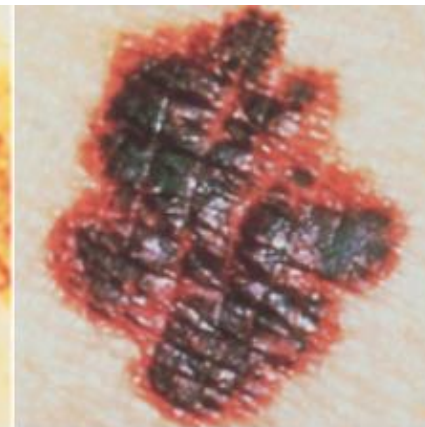


Malignant Melanoma (Cont.)

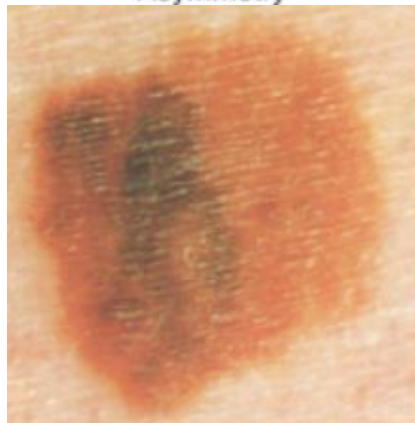
- (A) Asymmetrical
- (B) Borders irregular
- (C) Color variation
- (D) Diameter larger than pencil eraser
- (E) Elevated lesion



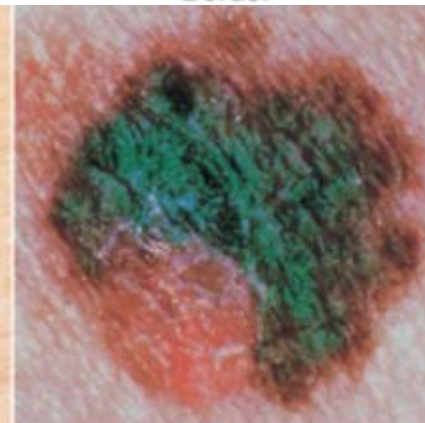
Asymmetry



Border



Color



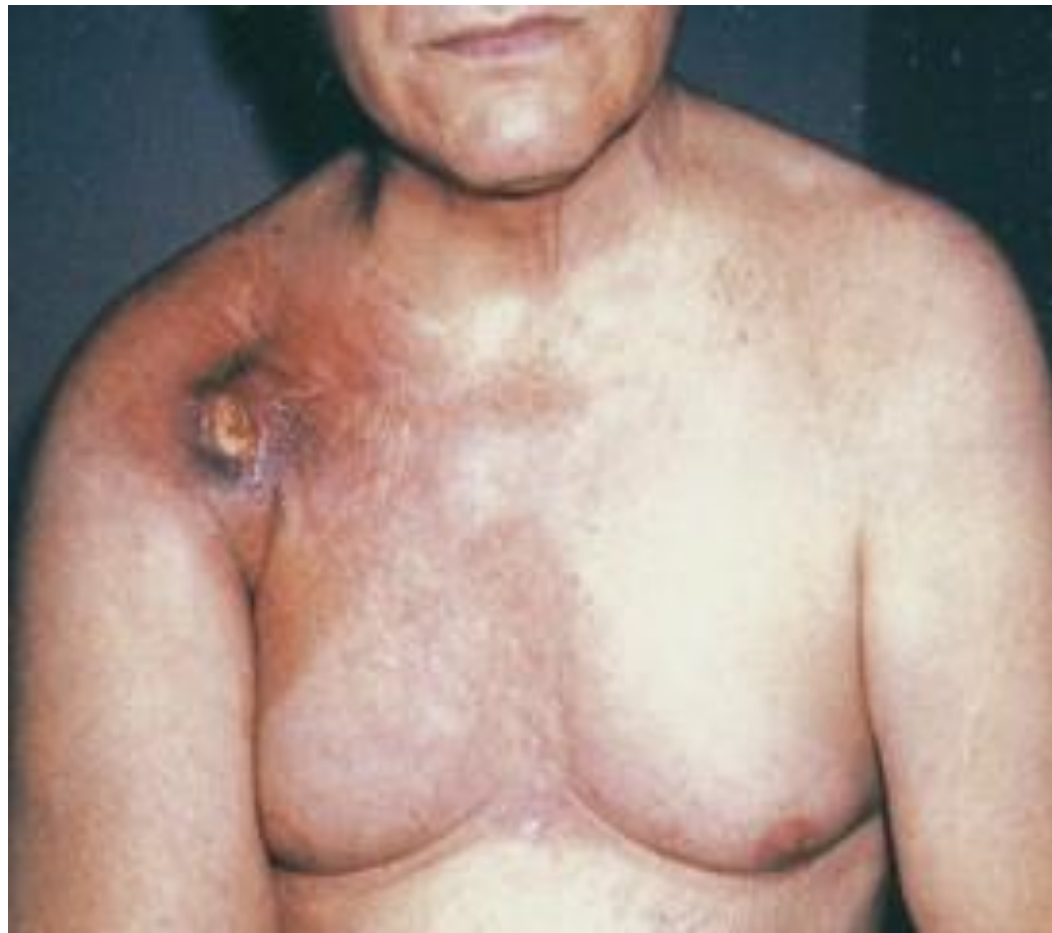Diameter

Skin, Hair, and Nails Seidel's Guide to Physical Examination. Published January 1, 2019. Pages 131-183. © 2019. FIG. 9.61. My Athens/ Clinical Key



Skin Cancers Plan

- Referral to Dermatology is required for positive findings

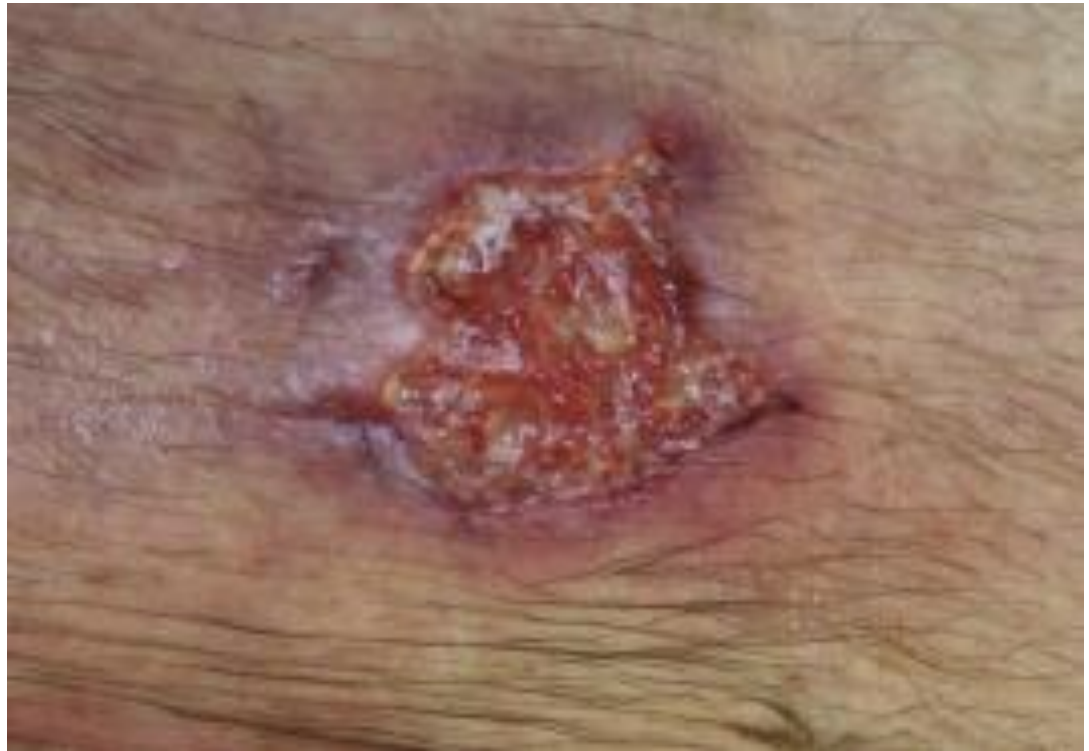

Skin Cancer Atlas of Diagnostic Oncology. Published January 2, 2010. Pages 446-483.
© 2010. FIGURE 13.41. My Athens/ Clinical Keys



Cancer Screening Test

- Screening and early detection
- 3 Point Checklist



Cutaneous Manifestations of Internal Disease Skin Disease: Diagnosis and Treatment. Published January 1, 2018. Pages 586-620. © 2018. Fig. 22.41. My Athens/ Clinical Key



Three-Point Checklist

- Based on 3 dermoscopic criteria:
 - Asymmetry of pattern and distribution
 - Atypical network
 - Blue-white structures

Checklist	
Asymmetry	<input checked="" type="checkbox"/>
Atypical network	<input type="checkbox"/>
Blue-white structures	<input checked="" type="checkbox"/>
Total score	2

Dermoscopy. Published January 1, 2012. Pages 1-32. © 2012. Figure 14. My Athens/ Clinical Key



Checklist Scoring

- One point is assigned to each criterion present
- Two points is considered positive



Enabling Objectives

- 1.52 Utilize the knowledge of integumentary system anatomy while assessing a patient with a integumentary complaint
- 1.53 Utilize the knowledge of integumentary system physiology while assessing a patient with a integumentary complaint
- 1.54 Identify types of lesions
- 1.55 Perform a dermatological examination




Enabling Objectives (Cont.)

- 1.56 State signs and symptoms of common dermatological disorders
- 1.57 State treatments for common dermatological disorder
- 1.16 State Red Flag criteria



Questions



R³

Relevant, Responsive, Requested

2.10.2-94



Application

- Integumentary System, Job Sheet SCSC 2.10-3
- SCSC Performance Test 10